Check for updates

Received: 11 April 2022 | Revised: 12 October 2022 | Accepted: 17 October 2022

DOI: 10.3322/caac.21766

REVIEW ARTICLE

Interventional gastroenterology in oncology

Vaibhav Wadhwa MD | Nicole Patel MD-DR, MBA | Dheera Grover MD | Faisal S. Ali MD | Nirav Thosani MD MHA

Center for Interventional Gastroenterology at UTHealth (iGUT), Division of Gastroenterology Hepatology and Nutrition, University of Texas Health Science Center, McGovern Medical School, Houston, Texas, USA

Correspondence
Nirav Thosani, Center for Interventional Gastroenterology at UTHealth (iGUT), Division of Gastroenterology Hepatology and Nutrition, University of Texas Health Science Center, McGovern Medical School, 6431 Fannin St, Houston, TX 77030, USA.
Email: nirav.thosani@uth.tmc.edu

Abstract

Cancer is one of the foremost health problems worldwide and is among the leading causes of death in the United States. Gastrointestinal tract cancers account for almost one third of the cancer-related mortality globally, making it one of the deadliest groups of cancers. Early diagnosis and prompt management are key to preventing cancer-related morbidity and mortality. With advancements in technology and endoscopic techniques, endoscopy has become the core in diagnosis and management of gastrointestinal tract cancers. In this extensive review, the authors discuss the role endoscopy plays in early detection, diagnosis, and management of esophageal, gastric, colorectal, pancreatic, ampullary, biliary tract, and small intestinal cancers.

KEYWORDS
cancer, cholangiocarcinoma, colon cancer, endoscopic ultrasound, endoscopy, esophageal cancer, gastric cancer, oncology, pancreatic cancer

INTRODUCTION

Cancer is one of the foremost health problems worldwide and is among the leading causes of death in the United States. It is estimated that approximately 1.9 million new cancer cases will be diagnosed in 2022 alone, and roughly 0.6 million cancer-related deaths are projected to occur by the end of 2022 in the United States.[1]

Globally, gastrointestinal (GI) tract cancers accounted for approximately 26% of the total global cancer incidence and for approximately 35% of all cancer-related mortality in 2018.[1] It is projected that the global burden of GI tract malignancies will amount to 7.5 million new cases, with 5.6 million mortalities, by 2040.[2] The incidence rate of all major GI tract cancers (i.e., esophageal, gastric, colorectal, liver, and pancreas) increased significantly in younger adults (aged 25–49 years) during the period from 1995 to 2014.[2]

In this review, we discuss the role of endoscopy in early the detection, diagnosis, and management of various GI tract cancers.

ESOPHAGEAL CANCER

Carcinoma of the esophagus is currently the sixth most common cause of cancer-related death and the seventh most common malignancy worldwide,[3] and it portends a poor prognosis because of its delayed diagnosis and advanced stage at the time of diagnosis, leading to a 5-year survival rate <20%.[4]

There are two primary subtypes of esophageal cancer, squamous cell carcinoma (SCC) and adenocarcinoma (EAC), and the majority of cases worldwide are SCC (90%).[3] The prevalence of EAC is currently more than that of SCC in the United States. The incidence of EAC is also on the rise, likely because of an increase in obesity, gastroesophageal reflux disease (GERD), and Barrett esophagus (BE). In addition, it is currently estimated that 20,640 cases of esophageal cancer will be diagnosed in the United States and approximately 16,410 cancer-related deaths are expected in the year 2022. The overall incidence of esophageal cancer is approximately 4.2 per 100,000 population in the United States.[2,4–6]

This is an open access article under the terms of the Creative Commons Attribution-NonCommercial-NoDerivs License, which permits use and distribution in any medium, provided the original work is properly cited, the use is non-commercial and no modifications or adaptations are made.
© 2022 The Authors. CA: A Cancer Journal for Clinicians published by Wiley Periodicals LLC on behalf of American Cancer Society.

Risk factors

Squamous cell carcinoma

Current population-based studies estimate that the incidence of esophageal SCC is approximately 1.2 per 100,000 population in the United States.[4] There is no sex predisposition in esophageal SCC, with men and women equally affected; however, there is a racial predilection, with a higher risk of developing esophageal SCC reported in African American populations than in Caucasian populations.[7,8]

The major risk factors implicated in the development of esophageal SCC are tobacco use and alcohol consumption, and less common risk factors include achalasia, palmoplantar keratoderma, prior caustic injury, and a prior history of aerodigestive cancers.[9] In developing countries, diets high in n-nitrosamines and frequent intake of hot beverages and pickled foods have also been identified as additional risk factors.[8]

Adenocarcinoma

Population-based studies estimate that the incidence of EAC is approximately 2.7 per 100,000 population in the United States.[4] There is significant sex disparity, with males four times more likely to be diagnosed with EAC than females. Caucasians are five times more likely to develop EAC than African Americans. The major risk factors for EAC include BE, obesity, smoking, and chronic GERD.[10] Consistent GERD symptoms are associated with a 5-fold to 7-fold increase in the development of EAC compared with individuals who have no symptoms or infrequent symptoms.[11] In part, this is because of the higher prevalence of BE in individuals who have chronic GERD compared with the general population.[12] Because BE is a premalignant condition for EAC, the role of endoscopy in this population is very significant, with applications in screening, diagnosis, and treatment.

Barrett esophagus

BE is a premalignant condition for EAC that is characterized by a change in the normal squamous epithelium of the distal esophagus, with metaplastic intestinal-type columnar epithelium.[13] The progression of BE to invasive EAC is step-wise and includes multiple stages, such as intestinal metaplasia (nondysplastic BE [NDBE]), low-grade dysplasia (LGD), high-grade dysplasia (HGD), intramucosal carcinoma (IMCA), and finally invasive EAC.[14] The annual risk of progression of BE to EAC depends on the histologic stage of BE. NDBE has an annual incidence from 0.2% to 0.5%, with a minor increase seen in LGD (0.7%) and a substantial increase seen in HGD (7%).[15,16] Factors associated with neoplastic progression include tobacco use, advanced age, central obesity, length of the BE segment, and lack of proton pump–inhibitor use.[12]

Endoscopic screening and surveillance

Screening for EAC is focused on the identification of BE. The most recent American College of Gastroenterology guideline on the diagnosis and management of BE recommends one-time screening for patients who have chronic GERD symptoms and three or more risk factors for BE (male sex, White race, age older than 50 years, obesity, tobacco smoking, and a family history of either BE or EAC in a first-degree relative).[17]

Surveillance for BE depends on the histologic grade of BE on index endoscopy. For NDBE, surveillance should be stratified by NDBE segment length: a 3-year surveillance interval is recommended for BE segments ≥3 cm, and a 5-year surveillance interval is recommended for shorter segments (<3 cm).[17] For BE with indefinite dysplasia that is confirmed by a second pathologist, repeat esophagogastroduodenoscopy (EGD) is recommended within 6 months of intensifying proton pump–inhibitor therapy (twice-daily dosing); if BE with indefinite dysplasia is reconfirmed, annual surveillance EGD is recommended.[17]

Endoscopic surveillance in BE for the detection of dysplasia is the current standard of care endorsed by all major GI societies; this is currently performed by obtaining random, four-quadrant biopsies at 1-cm to 2-cm intervals from the BE segment under white-light endoscopy (WLE), as outlined in the Seattle protocol.[18] Dysplasia, intestinal metaplasia, and EAC cannot be well characterized using WLE. Chromoendoscopy, which entails intraluminal dye application, is sometimes used with WLE to enhance mucosal morphology and improve diagnostic accuracy for the detection of premalignant lesions. A meta-analysis of studies comparing WLE versus WLE using chromoendoscopy found no significant difference in the detection of HGD and EAC between the two techniques.[19] In addition, chromoendoscopy is cumbersome, and the safety of luminal dye use has not been established in a robust manner. Narrow-band imaging (NBI) is a digital version of chromoendoscopy that allows for the enhancement of mucosal characteristics, which can assist in the identification of abnormal tissue and targeted biopsies, potentially increasing the yield of detecting precancerous lesions within BE lesions, with a pooled sensitivity and specificity of 76% (95% CI, 61%–91%) and 99% (95% CI, 99%–100%), respectively.[20] The use of NBI and the practice of NBI-directed biopsies is currently limited and, like WLE, is prone to sampling error. Wide-area transepithelial sampling, done as an adjunct to four-quadrant biopsies under WLE, has also been developed as a diagnostic modality to increase the diagnostic yield of premalignant lesions.[21] However, in the most recent BE guidelines by the American College of Gastroenterology, no recommendation could be made on the use of wide-area transepithelial sampling in BE surveillance, predominantly because of the lack of a clear gain in the diagnostic yield for premalignant lesions.

Nonendoscopic modalities for BE screening have emerged in recent years, notably, the Cytosponge (Medtronic GI Solutions), a polyester mesh sphere that is compressed within a gelatin capsule attached to a thread.[22] Developed with the intent to increase early detection of BE and premalignant lesions, the diagnostic utility of the Cytosponge has been studied in one large-scale, randomized trial,

which showed an absolute increase in BE detection of 18.3 per 1000 person-years (95% confidence interval, 14.8–21.8 per 1000 person-years).[23] The use of a Cytopsponge, combined with biomarker testing, has been recently endorsed as an acceptable alternative to endoscopy for screening for BE in patients who have chronic reflux symptoms and additional risk factors that could increase their pretest probability of developing intestinal metaplasia.

For BE with LGD that is confirmed by a second pathologist, surveillance EGD is recommended at 6 months from diagnosis, 12 months from diagnosis, and annually thereafter. Surveillance also depends on whether treatment is performed using radiofrequency ablation (RFA), cryotherapy, endoscopic mucosal resection (EMR), or endoscopic submucosal dissection (ESD).[17]

Role of endoscopy in the diagnosis of esophageal cancer

Esophageal cancer is diagnosed by performing an upper endoscopy with mucosal biopsies and subsequent confirmation by pathology.[12] This approach has very high sensitivity (>95%) when multiple samples are obtained.[24] In case of an obstructing mass, brush cytology may be used to increase sensitivity, but it is not routinely performed.[25] Ultrathin endoscopes are routinely used for obstructing masses to visualize the extent and length of the tumor. Sampling can be performed using these endoscopes as well.

For the detection of early stage carcinoma, magnification, chromoendoscopy, NBI, confocal microscopy, volumetric laser endomicroscopy, and other advanced imaging techniques are often used and have been shown to increase the dysplasia detection rate.[26]

Role of endoscopy in staging of esophageal cancer

Accurate pretreatment staging of esophageal cancer is of utmost importance to provide patients with an effective management plan and an appropriate prognosis. The latest National Comprehensive Cancer Institute (NCCN) Guidelines recommend a contrast-enhanced computed tomography (CT) scan of the chest and abdomen to rule out any distant metastases at the time of diagnosis.[27] A whole-body positron emission tomography scan with 18-fluorodeoxyglucose is recommended for patients without evidence of distant metastases followed by an endoscopic ultrasound (EUS) with or without fine-needle aspiration (FNA) or fine-needle biopsy (FNB) of extra-esophageal targets. EUS is recommended in cases where it will likely lead to a change in management and identify potentially curative cancer above stage.[26,28]

Role of EUS in staging

EUS is a minimally invasive endoscopic procedure with the use of an echoendoscope, which has an ultrasound probe at its tip that produces high-frequency sound waves, to visualize the layers of the GI wall and surrounding tissues.[28] For esophageal cancer, EUS is currently the most precise modality for locoregional staging. EUS can be used to evaluate the depth of extension of the primary tumor into the esophageal wall and surrounding tissues as well as locoregional adenopathy.[29]

For staging purposes, a circumferential evaluation is performed using a radial echoendoscope that provides a 360-degree view of the esophageal wall and the surrounding tissues. Because of the frequency at which the transducer operates, the echoendoscope is able to provide excellent resolution with depth of up to 4–5 cm of the surrounding tissue.[30,31] Because the image is perpendicular to the echoendoscope, image-guided interventions, such as FNA or FNB, cannot be performed using a radial echoendoscope. Therefore, if an extraesophageal target is identified, the scope is changed to a linear echoendoscope to facilitate interventions. This echoendoscope provides a 120-degree view of the esophageal wall and the surrounding structures in the plane of the echoendoscope, thereby allowing for FNA or FNB to be performed under real-time image guidance.[28]

In patients who have a mass identified that is nearly obstructing the lumen and does not allow passage of a regular upper endoscope, it is not possible to perform EUS with the regular echoendoscopes. In these cases, high-frequency, through-the-scope probes, called *EUS miniprobes*, are occasionally used. EUS miniprobes are passed through the operating channel of the diagnostic upper endoscope and, although they may be able to traverse the luminal narrowing, they have limited sonographic tissue penetration because of the high frequency (20–30 MHz) at which they operate at.[32] This limits their utility in obstructive cancer staging.

Esophageal cancer staging is best performed using the tumor, node, metastasis (TNM) staging system. The detailed examination of the esophageal wall using EUS helps in the accurate assessment of tumor depth and resultant staging. The differentiation between T1, T2, and T3 tumors is based on the degree of involvement of the muscularis propria layer (EUS layer 4).[28] If the tumor is superficial to muscularis propria with a visible plane, it is deemed to be T1. If tumor invasion is identified into, but not through, muscularis propria, it is classified as T2; but, if the tumor invades through the muscularis propria, it is deemed to be at least T3. Tumor invasion into adjacent structures and beyond is classified as T4.[28] The overall accuracy of EUS for T and N staging of esophageal cancer is approximately 90% in superficial and partially obstructing masses.[33] The accuracy declines in nearly obstructing masses where the echoendoscope is unable to pass through.

EUS may be useful in distinguishing between T1a and T1b lesions and should be routinely performed before proceeding with resection to rule out any nodal disease. This is important because the depth of invasion is directly related to the risk of lymph node metastasis.[34] T1a and T1b cancers of the upper one third of the submucosa (sm1) have an approximately 3%–6% risk of lymph node metastasis compared with 21%–24% for T1b tumors, tumors of the middle one third of the submucosa (sm2), and tumors of the bottom one third of the submucosa (sm3).[28] The sensitivity of EUS for T staging

esophageal cancer in T1 and T2 tumors is approximately 80%, but it is >90% in T3 and T4 tumors. A large systematic review of 27 studies showed that EUS was highly effective in differentiating between T1 or T2 cancers and T3 or T4 cancers. Because T3 and T4 cancers have a higher risk of nodal involvement, this distinction is necessary because it leads to a change in the management of these patients.[35]

Lymph node staging is performed by identifying the number of nodes present with malignant features. EUS features of malignant-appearing lymph nodes include round shape, hypoechoic appearance, an absence of central intranodal vessels, large size (>1 cm), and discrete borders.[36] The likelihood of a lymph node being malignant is higher with more features, and vice versa. The overall accuracy of EUS for N staging is reported to be >70%.[37,38]

Role of endoscopy in the treatment of esophageal cancer

Endoscopic therapies for esophageal cancer can be broadly classified into two major groups: curative and palliative. Curative therapies are used for BE with dysplasia, esophageal squamous dysplasia, early cancers, or mucosal cancers. Palliative therapies are used for patients who are not surgical candidates or are unwilling to undergo surgery.

Curative therapies

Patients who have dysplastic BE, esophageal squamous dysplasia, and IMCA are amenable to endoscopic eradication therapy (EET).[39] These patients are typically managed with use of either ablative therapies, such as RFA, cryotherapy, and argon plasma coagulation (APC), or resection modalities, such as EMR and ESD.[40] The type of therapy is based on the endoscopic appearance, with nonnodular mucosa generally managed by using ablative therapies and resection modalities for nodular mucosa. Ablative therapy is also performed after resection.

In patients who have early esophageal cancer (confined to mucosa or submucosa with no disease spread), appropriately selected EET can provide 2-year and 5-year survival rates comparable to those achieved with surgical resection. There is significant morbidity and mortality associated with esophagectomy; EET reduces the burden of adversities imposed by surgical intervention, which can have a considerable impact on patients' quality of life and thus is currently the standard of care for early esophageal cancers.[41,42]

Endoscopic ablation therapy

Radiofrequency ablation therapy

RFA is performed with the use of a bipolar probe to deliver thermal energy generated by radiofrequency waves to the esophageal mucosa, resulting in tissue destruction. Depending on the location and the extent of mucosa being treated, it can be done in a localized or a circumferential fashion. The use of RFA has been shown to be extremely effective in the eradication of dysplastic BE and thus reduces the risk of progression to EAC. In patients with HGD, ablation is recommended over esophagectomy or intensive endoscopic surveillance.[43] The role of ablative therapy in patients with nonnodular LGD has been debatable, with data suggesting a decrease in progression to HGD and EAC with the use of RFA.[40] An acceptable alternative in these patients can be annual surveillance endoscopy instead of ablative therapy. In addition, ablative therapy for NDBE is not recommended because of the low risk of progression to EAC in these patients and the risk of potential complications caused by ablation.[40]

The role of RFA in patients who have squamous cell dysplasia or superficial esophageal SCC (ESCC) is not well defined, with limited data available and mixed outcomes.[44] Preliminary evidence suggests that RFA can be performed safely for flat-type, noninvasive ESCC, even in patients with esophageal varices.[45] When appropriately selected, complete eradication of ESCC may be possible. However, a major limitation of this technique lies in the aggressive nature of ESCC; the identification of deep tissue invasion is critical to avoid undertreatment because even superficial ESCC carries the risk of lymph node metastasis.[46] Therefore, accurate preprocedural staging that can definitively assess deep tissue invasion and lymph node metastases is pivotal to the further development of RFA as a treatment modality for ESCC.

Argon plasma coagulation therapy

APC is the use of ionized argon gas (argon plasma) to apply a high-frequency current to tissues, which will induce cauterization and destruction. APC use in BE has an eradication rate of 66%–100%, with relapse rates of approximately 3%–11% per year.[47–49] APC has been associated with *buried* BE in the neosquamous epithelium postablation in as many as 20%–30% of cases.[50]

APC has been used in superficial ESCC, albeit in a limited manner, for patients who were not suitable candidates for endoscopic resection.[51] APC has also been used with favorable outcomes in patients who had a local recurrence after curative esophagectomy.[52] Although the reported cancer-eradication rate with the use of APC is up to 90%, the robustness of evidence is limited by a lack of studies with large samples and a lack of comparison with the standard of care. In addition, APC as a therapeutic modality may suffer from the same limitations as RFA, which reinforces the importance of accurate pretreatment staging of ESCC. Nonetheless, for patients who are poor surgical candidates, APC is an option that should be explored after obtaining a multidisciplinary consensus.

Compared with RFA, APC suffers from a narrow and nonuniform field of treatment and a higher complication rate. Therefore, in

routine clinical practice, APC is usually used as a second-line therapy after nonresponse to RFA.[53]

Cryoablation therapy

Cryoablation induces tissue destruction by the application of liquid nitrogen to the abnormal esophageal mucosa, which results in intensive, swift cooling and, ultimately, in tissue ischemia and apoptosis.[49] The rate of complete eradication from cryoablation therapy in dysplastic BE has been reported at 87%–96%.[54] Cryotherapy has also been shown to be effective in patients who have early adenocarcinoma or IMCA, with complete remission reported in approximately 75% of patients, including those who failed other endoscopic treatments.[55]

Endoscopic resection therapy (EMR and ESD)

EMR is considered to be a gold-standard treatment for the resection of short segments of nodular dysplasia and for the resection of superficial EAC and ESCC.[39] It is typically performed with the use of a cap-assisted device attached to the tip of the endoscope, creating a *pseudo-polyp* using suction into the cap and placing a rubber band around the base, which then can be resected using a snare. This technique is also known as *band-EMR*[40,56] (Figure 1).

ESD is a technique that allows for en-bloc resection of superficial lesions by performing careful dissection through the submucosa using cautery. The indications for using ESD over EMR are not well defined for EAC or ESCC. Expert consensus suggests that ESD may be considered in cases with a higher likelihood of invasiveness (IMCA on biopsy, equivocal histology on biopsy, and bulky tumors) and in cases where EMR may not be feasible (nonlifting lesions, recurrent lesions).[57] Compared with EMR, ESD had higher en-bloc and curative resection rates in a randomized trial. A meta-analysis of eight studies showed that ESD achieved en-bloc resection in 97% of patients versus 49% with EMR, irrespective of lesion diameter.[58] The local recurrence rate with ESD was also lower (0.3% vs. 11.5% with EMR). It is worth noting that ESD requires additional endoscopic expertise, which is not readily available at all centers in the United States, has longer procedure times, and does not have an established reimbursement structure in the United States. Furthermore, currently, there remains reluctance among the medical and surgical oncologic communities to the adoption of ESD as a potential standard of care for tumors in patients who are currently deemed to be surgical candidates. As our experience with endoscopic resection in the West grows, overcoming these obstacles will be pivotal to the appropriate adoption of ESD.[59]

It has been demonstrated that endoscopic resection is highly effective in the removal of HGD and T1a EAC in 91%–98% of cases.[39] The curative and survival rates of endoscopic resection of T1a lesions have been comparable to the rates of surgical resection with significantly decreased morbidity and mortality.[60] Postendoscopic resection treatment with additional resection or ablation of residual BE dramatically decreases the risk of metachronous HGD or EAC.

As mentioned above, T1b EAC has an elevated risk of lymph node metastasis.[61] The depth of submucosal invasion is significantly associated with the risk of lymphovascular invasion, with minimal risk seen in disease limited to the upper one third of the submucosa (sm1 tumors). Deeper invasion beyond sm1 is highly predictive of lymph node metastasis and thus is not considered appropriate for curative endoscopic resection. Endoscopic resection may be approached for a T1b lesion on a case-by-case basis.

Endoscopic ultrasound-guided fiducial placement

Neoadjuvant or adjuvant radiotherapy (RT) is a pivotal component of therapy for EAC. One major obstacle hindering the accuracy of RT in EAC is difficulty in the delineation of true tumor extent on CT scans used for RT planning. Endoscopic fiducial marker placement aims to counter this limitation because it allows identification of the cranial and caudal mucosa extent of the tumor; this assists in daily image-guided RT planning and execution with improved accuracy.[62,63] A linear array echoendoscope can be used for fiducial placement. Solid-gold markers with fixed dimensions; flexible-gold markers, which are coil-shaped; and radiopaque hydrogel markers have been studied in patients with EAC.[64] Over time, while undergoing RT, the relatively improved visibility of flexible-gold markers, compared with solid-gold and hydrogel markers, has been demonstrated in a prospective, single-center, nonrandomized study. Currently, the use of fiducial markers for RT assistance in EAC is limited to tertiary centers. Future experience and evidence may increase adoption of this technology, as has been the case with various other solid tumors, notably, prostate cancer, because this would enable dose escalation while minimizing off-target effects of radiation.

Palliative therapy

In patients with advanced disease who are not candidates for endoscopic or surgical resection, the role of endoscopy is geared toward palliation of symptoms, optimization of nutritional status, and preservation of quality of life. Dysphagia caused by esophageal obstruction is a major concern in these patients. Endoscopic options for the palliation of dysphagia include luminal stenting, dilation, and chemical or ablative debulking.[65]

Dilation of the esophageal lumen may provide temporary relief and is not recommended because of the high risk of complications. Esophageal stenting is currently the preferred and durable method of providing symptom relief.

Self-expandable metal stents (SEMS) are the most preferred type of stents, with different variations available, such as uncovered, fully covered, or partially covered SEMS.[66] Fully covered

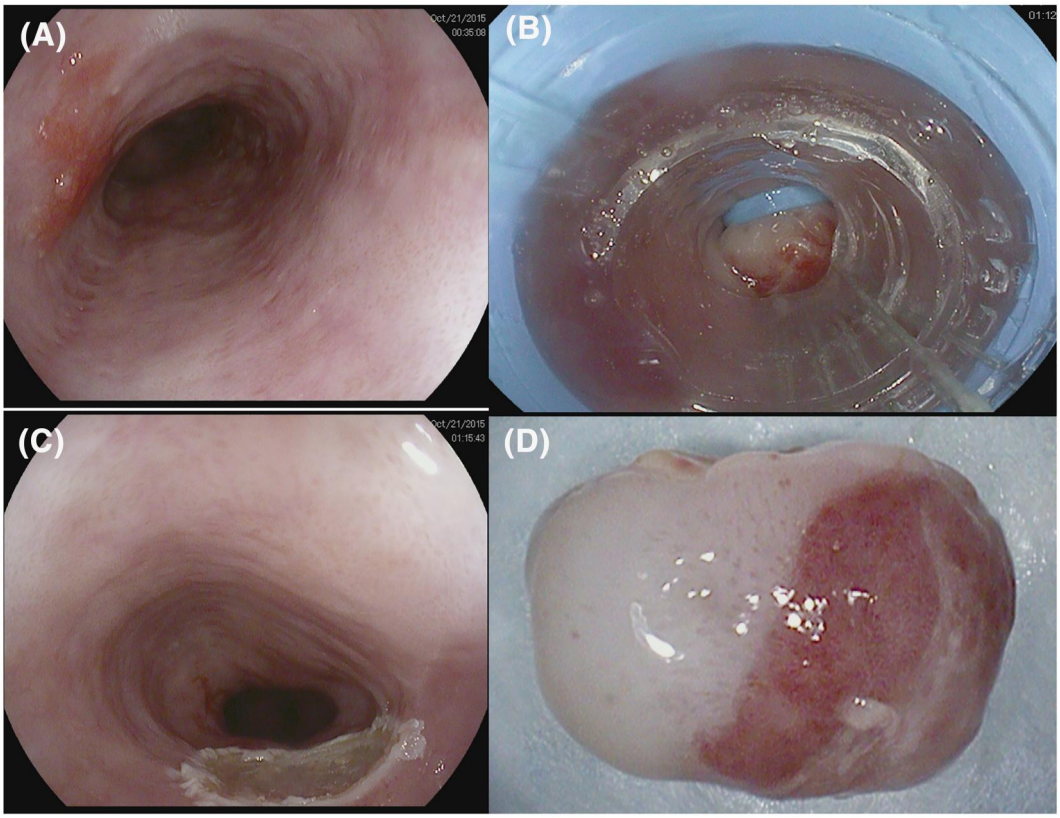

FIGURE 1 Nodular Barrett esophagus endoscopic mucosal resection: (A) Nodular Barrett esophagus, (B) band placed on nodular Barrett esophagus, (C) postresection base, (D) resected specimen.

SEMS are the most common type of stents used in current clinical practice.[67] Multiple studies have shown that covered SEMS are superior to both uncovered SEMS and covered plastic stents because of the low risk of tumor ingrowth and stent migration. When comparing fully covered versus partially covered SEMS, there was no significant difference in the rates of recurrent dysphagia or any other complications poststent placement.[68] SEMS can also be used for the palliation of tracheoesophageal fistula that develops because of tumor infiltration or posttreatment effects of RT. SEMS seal the esophagus from the airway, help in the prevention of aspiration of luminal contents, and can also lead to successful closure of the defect.[69] Overall stent placement is well tolerated and provides durable relief of dysphagia and improvement in quality of life, but it is associated with several infrequent complications, such as migration, bleeding, tumor ingrowth, fistula formation, chest pain, and perforation.

Debulking can be considered on a case-by-case basis in patients who have an inoperable tumor causing obstruction.[70] Endoscopic techniques described for debulking include chemical debulking, photodynamic therapy (PDT), and laser therapy (neodymium-doped yttrium aluminum garnet [Nd:YAG]). Chemical debulking is performed by using an absolute alcohol injection directly into the tumor. This only provides transient relief and needs to be repeated multiple times. Laser therapy with Nd:YAG has similar efficacy but a higher incidence of perforation compared with PDT.[71] A randomized comparison of laser therapy (Nd:YAG) with esophageal stenting for palliation did show improved median survival in patients who received Nd:YAG, but there was no significant difference in dysphagia relief or quality-of-life scores. PDT involves the endoscopic delivery of light after deploying a photosensitizing agent, eventually leading to tissue necrosis by the production of reactive oxygen species. PDT can be used in mucosal and submucosal cancers that are difficult to resect endoscopically and in the case of recurrence after chemoradiotherapy.[72,73] Compared with Nd:YAG, PDT may provide a better treatment response rate with a relatively better safety profile based on data from a single randomized study. However, it is worth noting that PDT is associated with esophageal stenosis, photosensitivity, and esophagoaortic fistulae, which can be fatal, and as such is considered a major limitation of this treatment modality.

There is a growing body of evidence on the use cryoablation for debulking inoperable tumors for the relief of tumor-associated dysphagia.[74–76] Preliminary evidence suggests that cryoablation can obviate the need for esophageal stent placement. In cases where stents are eventually needed, data suggest that cryoablation may delay the need for stent insertion by 1 year. The adverse events associated with cryoablation also seem to be relatively less than those associated with PDT and Nd:YAG.

Evidence on endoscopic modalities for tumor debulking is generally limited to observational data, with a few prospective studies. As such, one should be mindful of the limitations while assessing the safety and efficacy of these treatment modalities for the palliation of esophageal cancer.

Take-home points

- Endoscopy and biopsies are the gold standard for diagnosing esophageal cancer.
- Endoscopic surveillance of intestinal metaplasia is recommended for patients who are at increased risk for esophageal cancer.
- EUS is currently the most precise modality for locoregional staging and thus is recommended for staging all esophageal cancers.
- Endoscopic ablation is recommended for all dysplastic BE.
- Endoscopic resection using EMR is the preferred modality for resection of nodular BE.
- Endoscopic resection using EMR or ESD is recommended for the treatment of early esophageal cancer (T1a) but should be performed at high-volume centers.
- Postresection ablative therapy is associated with a decreased risk of recurrence or metachronous cancer.
- Enteral stenting using SEMS is the preferred palliative measure for patients who present with a large esophageal mass causing obstruction.

GASTRIC CANCER

Gastric cancer was the fifth most commonly diagnosed cancer in 2018 and the third most common cause of cancer-related mortality worldwide.[77] Greater than 50% of new gastric cancer cases occur in the Asia Pacific region, with Latin American and Eastern European countries summing up the majority of the global burden. It is estimated that 26,380 cases of gastric cancer will be diagnosed in 2022 in the United States, and approximately 11,090 cancer-related deaths are expected.[6]

Risk factors

Several risk factors have been implicated in the development of gastric cancer. *Helicobacter pylori* infection is the strongest risk factor for the development of gastric adenocarcinoma.[78] *H. pylori* causes chronic gastritis, which progresses to neoplasia in a small percentage of patients. Other risk factors include atrophic gastritis, smoking, and hereditary disease (hereditary diffuse gastric cancer, Lynch syndrome, familial adenomatous polyposis, Peutz–Jeghers syndrome, and Li–Fraumeni syndrome).[79] Other possible risk factors include diet, lifestyle diseases, and Epstein–Barr viral infection.

Gastric intestinal metaplasia (GIM) is a premalignant condition for the development of gastric adenocarcinoma with a reported annual risk of 0.16%.[80] GIM is currently subclassified as a complete type or an incomplete type. Complete GIM resembles small intestinal mucosa, with eosinophilic enterocytes and well defined brush borders and goblet cells that are well formed, with the occasional presence of Paneth cells. Incomplete GIM resembles colonic mucosa, demonstrating multiple, irregular, cytoplasmic mucin droplets of variable size without brush borders.[81] Patients with GIM who have the incomplete type have a higher risk of gastric cancer compared with those who have the complete type (relative risk, 3.3).[82]

Diagnosis

Gastric adenocarcinoma, which is the most common type of gastric cancer, typically presents as a mass lesion but can also present as a nonhealing ulcer or as a diffuse, infiltrative form called *linitis plastica*. It is diagnosed by performing an upper endoscopy with mucosal biopsies and subsequent confirmation by pathology.[83]

Although obtaining a biopsy of the mass or abnormal mucosa may be straight forward, diagnosing linitis plastica can be quite difficult: superficial biopsies may not be revealing because there is infiltration of submucosa and/or muscularis mucosa of the stomach. Large mucosal biopsies using a *bite-on-bite* approach or submucosal biopsies with a snare may be taken.[84] EUS-guided FNB (EUS-FNB) may be helpful in obtaining a diagnosis in such cases and may help in an evaluation for locoregional lymphadenopathy at the same time.[85] In case of a malignant-appearing gastric ulcer, at least seven biopsies of the edges and base must be performed.[24]

Staging

Accurate pretreatment staging of gastric cancer is important to provide patients with an effective management plan and an appropriate prognosis. According to the latest NCCN Guidelines, it is recommended to obtain a contrast-enhanced CT scan of the chest and abdomen to rule out any distant metastases at the time of diagnosis.[86] In the absence of metastatic disease, EUS with or without biopsy should be performed to facilitate staging.

Role of EUS in staging

EUS is useful in the evaluation of tumor extension into the gastric walls and the surrounding tissues. For gastric cancer, EUS is most

useful in identifying patients with early gastric cancer, who may benefit from endoscopic resection or upfront surgery.[86] More specifically, EUS can provide accurate T staging and can successfully distinguish T1a tumors from T1b and T2 tumors.

Gastric cancer staging is best performed using the TNM staging system.[87] A detailed examination of the gastric wall using EUS helps in the accurate assessment of tumor depth and resultant staging. The differentiation between T1, T2, and T3 tumors is based on the degree of involvement of the muscularis propria layer (EUS layer 4). If the tumor is superficial to muscularis propria with a visible plane, it is deemed to be T1. The tumor is considered T1a when it invades into the lamina propria and T1b when it involves the submucosa.

If tumor invasion is identified into, but not through, the muscularis propria, it is classified as T2; however, if the tumor invades through the muscularis propria into the serosa, it is deemed to be at least T3. Tumor invasion into adjacent structures and beyond is classified as T4. T4 lesions invade the visceral peritoneum (T4a appears as loss of the clear line recognized as the serosa), or a local organ (such as liver, pancreas, spleen, diaphragm; T4b), or a large vessel (aorta, celiac axis).

EUS can differentiate T1–T2 from T3–T4 tumors with 86% sensitivity (95% CI, 81%–90%) and 91% specificity (95% CI, 89%–93%). EUS is less accurate for diagnosing lymph node metastases, with 69% sensitivity (95% CI, 63%–74%) and 84% specificity (95% CI, 81%–88%).[88] A recent network meta-analysis comparing EUS with CT for gastric cancer staging concluded that EUS was superior to CT for T1 and N staging, but no differences were noted in T2–T4 lesions.[89]

EUS may be useful for distinguishing between T1a and T1b lesions but remains suboptimal compared with EMR and ESD, which are the best modalities for determining the depth of invasion. However, similar to esophageal lesions, EUS should be routinely performed before proceeding with resection to rule out any nodal disease.

Role of endoscopy in the treatment of gastric cancer

Endoscopic therapies for gastric cancer can be broadly classified into two major groups: curative and palliative. Curative therapies are used for early gastric cancers or mucosal cancers. Palliative therapies are used for patients who are not surgical candidates or who are unwilling to undergo surgery.[83]

Curative therapies

Patients who have early gastric cancer without any lymph node metastases can potentially be cured using endoscopic resection therapies. ESD is the most commonly recommended resection modality used given its ability to resect the lesion en bloc and thus providing accurate margin assessment[90] (Figure 2).

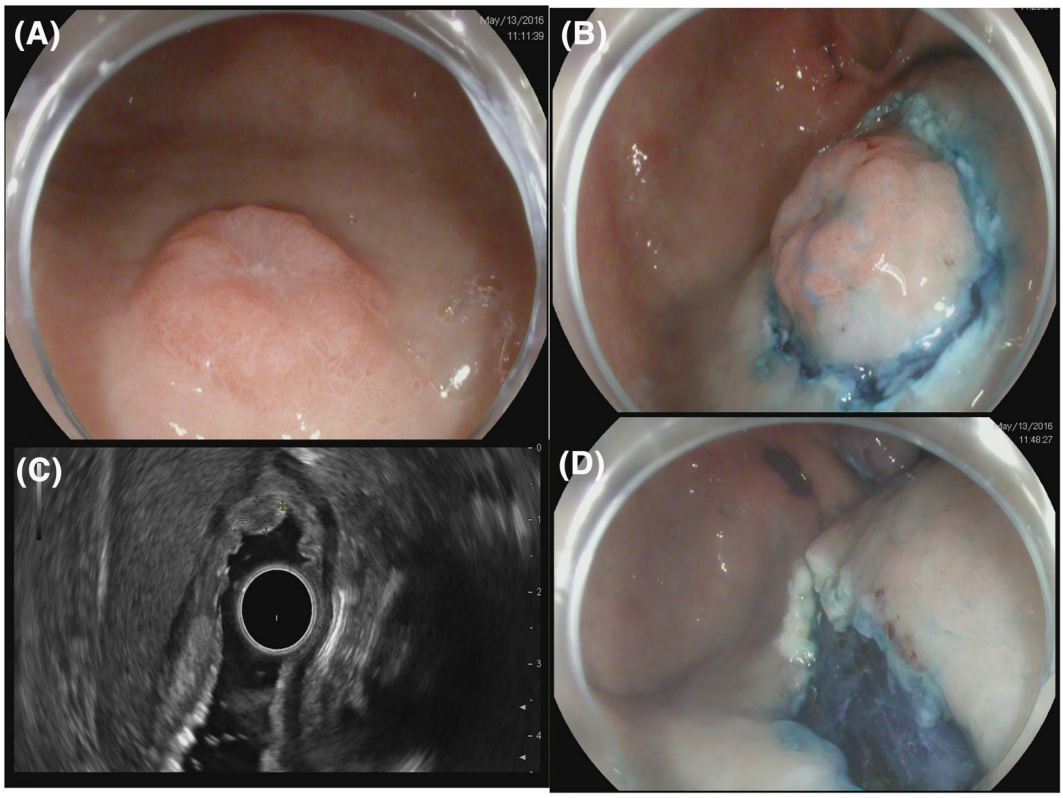

FIGURE 2 Endoscopic submucosal dissection for early gastric cancer: (A) Early gastric cancer, (B) endoscopic ultrasound showing a T1a lesion, (C) circumferential incision, (D) postresection.

ESD facilitates the complete removal of a tumor by performing a deeper resection and curative resection of lesions that are too large for en-bloc resection compared with EMR.[90] The absolute indications for ESD include moderately and well differentiated mucosal lesions that are nonulcerated and measure ≤2 cm.[90] Other expanded indications include moderately and well differentiated superficial lesions measuring >2 cm but ≤3 cm that have ulceration or contain early submucosal invasion and poorly differentiated, superficial lesions measuring ≤2 cm.

The risk of lymph node metastasis when ESD is performed for expanded indications is higher than when it is performed for absolute indications. However, the overall risk is still quite low.

In a fairly large meta-analysis of ≥9700 patients, the rate of lymph node metastasis was 0.2% for those who met the absolute criteria compared with 0.7% for those who met the expanded criteria.[91] Lesions with submucosal invasion and poor differentiation were associated with a higher incidence of lymph node metastasis (approximately 2.5%).

The 2019 American Gastroenterology Association clinical practice update recommended ESD as first-line therapy for visible, endoscopically resectable, superficial gastric neoplasia.[92] The data backing this have been limited to small, single-center studies, with a significant paucity of data from North America. A large, multicenter ESD outcomes study was recently published and reported >90% en-bloc and >80% R0 resection rates.[93] There was a 6.6% perforation rate, a 2.6% delayed bleeding rate, and a 3.9% rate of recurrence. All recurrences occurred in noncurative resections.

Palliative therapy

Similar to esophageal cancer, for patients with advanced cancer who are not candidates for endoscopic or surgical resection, endoscopic therapy is geared toward improving symptoms and nutritional status. Patients with advanced gastric cancer may present with narrowing of the antrum, pylorus, or duodenum, resulting in delayed or failed passage of gastric contents beyond this area. Patients who develop this present with early satiety, weight loss, recurrent nausea, vomiting, and ongoing abdominal pain.

The endoscopic options for palliation include enteral stenting and, most recently, an endoscopic approach to gastrojejunostomy (GJ) using EUS (EUS-GJ).

Endoscopic stent placement has been shown to be safe and effective for long-term relief in such patients. Several studies have compared endoscopic stent placement versus surgical GJ with similar technical and clinical success rates and a better safety profile. This is despite a general selection bias in the published body of evidence in favor of surgery because patients who are deemed surgical candidates have a better performance status.[94,95] The type of stent that may be used for this purpose may depend on local availability and expertise, but the most common type of stent used in clinical practice is an uncovered SEMS (Figure 3). Of note, covered duodenal SEMS are not available in the United States.

EUS-GJ is a relatively new technique that is increasingly used as a therapeutic option for the palliation of malignant gastric outlet obstruction at high-volume tertiary care centers. EUS is used to

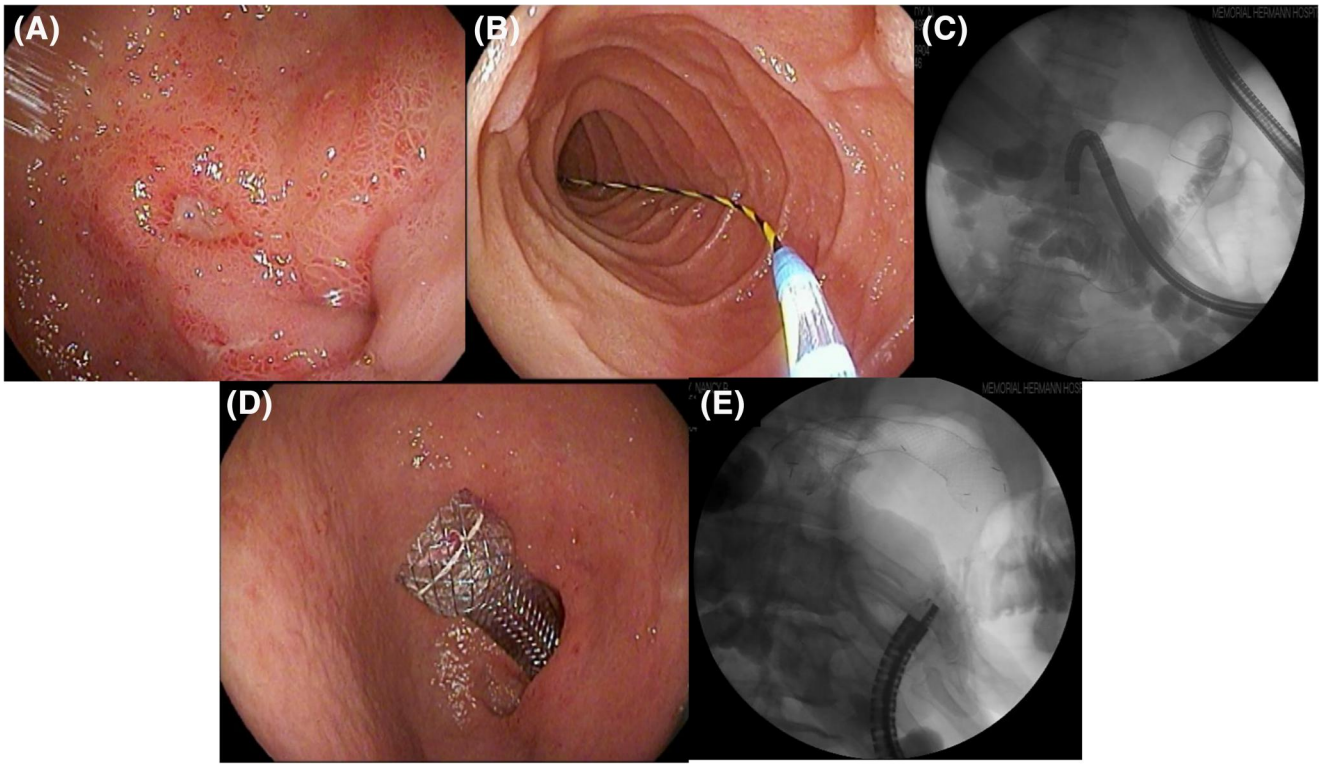

FIGURE 3 Duodenal stent for malignant gastric outlet obstruction: (A) Malignant duodenal stricture, (B) wire advanced beyond stricture, (C) fluoroscopic image of wire advanced beyond stricture, (D) duodenal stent placed, (E) final fluoroscopic image of stent.

identify and access the jejunal loop beyond the area of obstruction from within the stomach, and placement of a lumen-apposing metal stent is performed to create a GJ. The application of a lumen-apposing metal stent for this purpose is considered an off-label use. A systematic review and meta-analysis of 199 patients who underwent EUS-GJ for both benign and malignant etiologies showed a high technical success rate (92.6%) but a significantly high adverse event rate (5.6%) and re-intervention rate (11.5%).[96] Further prospective comparative studies are needed to compare EUS-GJ with enteral stenting and surgical GJ.

Take-home points

- Endoscopy and biopsies are the gold standard for diagnosing gastric cancer.
- Endoscopic surveillance of gastric intestinal metaplasia is recommended for patients who are at increased risk for gastric cancer.
- EUS is recommended for staging of nonmetastatic gastric cancer.
- EUS staging can help distinguish early gastric cancer and has potential therapeutic implications.
- ESD is recommended for the treatment of early gastric cancer but should be performed at high-volume centers.
- Enteral stenting is the preferred palliative measure for patients presenting with malignant gastric outlet obstruction.
- EUS-guided GJ is a new technique that can be offered to patients who have failed enteral stenting and are poor surgical candidates.

COLON CANCER

Incidence and prevalence

Colorectal cancer (CRC) is currently the third most common cancer in the United States and the second most common cause of cancer-related deaths.[97] The incidence of CRC has been decreasing in the past 2 decades, largely because of the adoption of screening programs.[98,99] By 2030, the global burden of CRC is projected to increase by 60%, with more than 2.2 million new cases and 1.1 million deaths.

In 2022, the National Cancer Institute estimates there will be 151,030 newly diagnosed CRC cases in the United States, including 80,690 males (53.4%) and 70,340 females (46.6%).[6] Of the newly diagnosed cases, 21.9% of patients are expected to be younger than 54 years. The incidence of CRC increases with age. However, recently, there has been a large increase in the number of young individuals being diagnosed with CRC, specifically, a 2% increase in incidence among men and women younger than 50 years. Many attribute this rise to earlier screening measures.[100] However, the current Western diet, which is dominated by processed and ultra-processed products, and a rise in the obesity epidemic may also be notable contributing factors that are modifiable.[101,102] By 2030, there will be expected increases of 90.0% and 124.2% in the incidence of colon and rectal cancer, respectively, among individuals aged 20–34 years and of 27.7% and 46.0%, respectively, among those aged 35–49 years.

The most common anatomic location of CRC varies by age group, with older individuals showing a higher proximal incidence because of various underlying predisposing factors.[103] Higher incidence of CRC has been noted in certain racial and ethnic groups. Specifically, non-Hispanic Black individuals have the highest incidence rate (52.7 per 100,000), followed by American Indians and Alaska Natives (43.4 per 100,000), then Asians and Pacific Islanders (29.8 per 100,000).[103,104] In 2021, the number of expected deaths was 52,980 (8.7% of all deaths), including 28,520 males and 24,460 females. This is higher than the 2014–2018 adjusted annual death rate of 13.7 per 100,000. Along with incidence, the death rate is also highest in the non-Hispanic Black population. Data suggest that approximately 4.1% of all individuals can be diagnosed with CRC at any point in their lives.[104] However, because of effective screening measures, early intervention, and better treatment options, the 5-year survival rate is reportedly as high as 64.7% (90.7% in localized CRC).

Risk factors

Along with age, multiple environmental and genetic factors are thought to alter the pathogenesis of CRC. The genetic role in the pathogenesis of CRC has been well established; however, most cases are sporadic.[105] Several modifiable and nonmodifiable risk factors have been identified in the pathogenesis of CRC. Smoking,[106] obesity,[107] consumption of alcohol (particularly those who consume >50 g per day),[108,109] physical activity,[110] and processed or red meats[111] are well established modifiable risk factors that have been known to increase the incidence of CRC. The nonmodifiable risk factors include age, ethnicity (higher risk in African Americans), sex (higher risk in males), personal history of inflammatory bowel disease,[112–114] history of primary sclerosing cholangitis, and family history of CRC.

Interestingly, an increase in inflammatory bowel disease activity is not associated with an increase in the incidence of CRC, and anti-inflammatory treatments, including mesalamine, are not shown to have a chemoprotective effect.[115] In contrast, a meta-analysis conducted in 2017 revealed that thiopurine use in patients with inflammatory bowel disease, particularly ulcerative colitis, led to a protective effect against developing CRC.[116] Similarly, antitumor necrosis factor therapeutics have also been shown to have a protective effect against developing CRC.[117]

Several modalities have been identified that protect against the development of malignancy. The role of dietary modifications,

including a high-fiber diet,[118] polyethylene glycol,[119] Vitamin B2,[120] Vitamin D,[121] calcium, dairy products,[122] and caffeine,[123] is being extensively studied. Aspirin has been shown to decrease CRC risk by 29%, which is explained by its anti-inflammatory action on the gut mucosa.[124,125] Recent data have supported the use of aspirin as a primary chemoprotective agent in certain subgroups of the population in the United States but not for routine use. A systematic review conducted by the US Preventative Services Task Force revealed a 40% reduction in the risk of CRC among individuals using aspirin for 10–19 years.[126] There was no effect on CRC incidence or mortality within 10 years of aspirin use. The most recent American College of Gastroenterology guidelines suggest that low-dose aspirin can be used for individuals aged 50–69 years who have a risk of cardiovascular disease ≥10%, are willing to take aspirin for 10 years, and are not at increased risk of bleeding.[127]

Role of colonoscopy in screening and diagnosis of colon cancer

Colonoscopy is a one-step CRC screening modality because it allows for the detection and resection of early stage CRC as well as precancerous polyps. Therefore, colonoscopy is the most commonly used CRC screening modality. The efficacy of colonoscopy in reducing incidence and mortality attributed to CRC is well established and is the basis for guideline endorsement of colonoscopy for CRC screening, which starts at age 45 years.[127] For individuals with a family history of CRC in a first-degree relative, it is recommended that CRC screening should begin 10 years before the age of the relative's diagnosis. The fecal immunochemical test (FIT) is an alternative to colonoscopy for CRC screening. However, if the test is positive, FIT has to be followed by a colonoscopy. For patients who cannot undergo colonoscopy or FIT, alternatives for CRC screening include a flexible sigmoidoscopy, a CT colonography or colon capsule study, and multitarget stool DNA testing. Of note, these alternatives are recommended conditionally based on evidence with very low certainty; colonoscopy and FIT are the only modalities with a robust body of evidence.

The role of endoscopy in CRC is not limited only to the visualization of precancerous lesions but also includes staging, localization, and treatment of these cancerous lesions. The evaluation of and possible intervention in these precancerous lesions endoscopically helps in early diagnosis and has led to decreased mortality. Every lesion detected through colonoscopy should be carefully assessed for morphologic features and vascular patterns. The NCCN Guidelines recommend marking the site at the time of colonoscopy if there is a suspicion of cancer or within 2 weeks of polypectomy when the pathology is known.[128] The marking is widely done by tattooing using an injection needle and permanent ink, ideally a few centimeters proximally and distally to facilitate visualization during surgery. It is considered the most effective method and is visible at surgery for up to 5 months.[129,130] Other uncommon methods of marking a lesion include taking an abdominal radiograph with the tip of the endoscope at the site of location or placing a metallic clip at the lesion site and taking a radiograph.[131]

Staging of colorectal cancer

Most CRCs arise from polyps. which take a considerable amount of time for malignant transformation. The polyp is malignant when the lesion with dysplastic changes invades the submucosa without extension into the muscularis propria.[132] The polyp is termed *carcinoma in situ* when it has not penetrated the submucosa. Such lesions do not have the propensity to metastasize into lymph nodes.[133]

The approach proposed by the American Joint Committee on Cancer (AJCC) in their *AJCC Cancer Staging Manual*, now in its eighth version (published in 2016), has set the standard for staging cancers.[132] The new staging edition attempted to lean toward a more personalized approach while staging patients by integrating biologic and molecular markers. The major difference between the current edition and prior editions is the inclusion of a stage for patients who have peritoneal metastasis: *stage IVC*.[134] Studies have shown that 5-year disease-free survival and overall survival were significantly shorter for patients who had stage IVC CRC compared with those who had stage IVB CRC. In addition to vascular or lymphatic infiltration and tumor deposition, the AJCC also recommends using microsatellite instability and *BRAF* gene mutation status as prognostic factors,[135–138] It also recommends *BRAF* mutation, *KRAS* mutation, and *NRAS* gene degeneration as predictors of efficacy.[134]

Approximately 50%–60% of patients who are diagnosed with CRC develop metastasis, mainly in the liver, and metastatic liver disease is the most common cause of mortality.[139–141] Because CRC treatment depends on TNM stage, it is essential to stage CRC judiciously. Stage 0 and I CRCs can be treated with surgical excision and RT. Because of the high rates of recurrence and metastasis in stage II and III CRCs after surgical excision and RT alone, a combined approach of surgical excision, chemotherapy, and RT is recommended in such patients.[142] Preoperative RT with chemotherapy may improve surgical resection rates in patients who have locally advanced, unresectable cancer.[143]

Role of EUS in staging

Precise staging is essential for appropriate management options, particularly in patients with rectal cancer. EUS can evaluate the depth of extension of the primary tumor into the rectal wall and surrounding tissues as well as locoregional adenopathy.

According to an earlier meta-analysis, the pooled sensitivity of EUS for rectal tumor invasion or depth of tumor (T classification) was noted to be as high as 88%–95%, and it was higher for patients who had advanced-stage disease compared with those who had early stage disease.[59] For detecting the T classification, specificity reached as high as 99%.[144] These findings were in concordance with other studies.[145]

A prior study compared EUS staging versus postoperative histology findings, and EUS detected the T classification correctly in 76% of patients. Over-staging and understaging were noted in 14% and 10% of patients, respectively, with inaccurate staging mainly in the T2 and T3 categories.[146] The authors thought that understaging was caused by difficulty in visualization and that over-staging was caused by the accumulation of inflammatory secretions around the tumor. Over-staging was significantly more common in patients who had minimally invasive T3 tumors identified by EUS (50%) than in those who had advanced T2 tumors (4%). The above findings argue against using neoadjuvant therapy in tumors classified as T3 because of concerns of over-staging. The study also concluded that the accuracy for EUS for nodal staging was as low as 57%. Other studies have also concluded that the accuracy for detecting nodal metastasis was low.

Multiple imaging modalities, including CT, magnetic resonance imaging (MRI), and EUS, have been studied and compared to determine their accuracy for staging CRC. A meta-analysis conducted in 2019 compared the accuracy of EUS versus MRI.[147] In that study, the pooled sensitivity and specificity of T classification were 79% and 89%, respectively, for EUS and 79% and 85%, respectively, for MRI. Pooled sensitivity and specificity in N staging were 81% and 88%, respectively, for EUS and 83% and 90%, respectively, for MRI. EUS was superior compared with MRI in overall T, overall N, T1, and T3 classification. MRI was better than EUS in T2 classification ($p < .01$). Therefore, there is no uniform consensus on the best modality for staging of CRC. Compared with CT and MRI, EUS may have better diagnostic accuracy for T classification versus other cross-sectional imaging tests. Still, the accuracy of nodal classification was modest for EUS (67% sensitivity and 78% specificity) and did not differ statistically among the three imaging modalities.[148,149]

Recent advances in CT and MRI techniques have improved the diagnostic accuracy of these modalities. Thin-section MRI has been shown to accurately indicate the tumor staging of rectal cancer and the depth of extramural tumor infiltration.[150] Similarly, adding multiplanar reconstructions with multiphasic, contrast-enhanced, multidetector-row CT has been shown to improve the accuracy of staging rectal cancer.[151]

A large meta-analysis, including 89 studies, compared CT, MRI, and EUS for diagnostic accuracy in rectal cancer. The authors found that the sensitivities of EUS, CT, and MRI were similar, but MRI had the highest specificity at 89%. There was no significant difference in diagnostic accuracy between EUS, CT, and MRI.[152] Another study showed that EUS and MRI had comparable diagnostic accuracy, and MRI was noted to be more sensitive than CT and EUS.[153]

Role of endoscopy in the treatment of colon cancer

Endoscopic resection

With the advancements in endoscopic techniques, there has been a significant shift away from surgeries to minimally invasive procedures for CRC treatment. Successful removal of adenomas during colonoscopy has been shown to decrease mortality up to 50%.[154,155] The US Multi-Society Task Force strongly recommends documentation of an endoscopic description of the lesion, including size, location, and morphology, in colonoscopy.[155] Removing sessile or polypoidal lesions using the safest, most efficient, and most complete option available is recommended.

Cold-snare polypectomy is recommended for diminutive (≦5 mm) and small lesions (6–9 mm). There are no differences in the complete resection, adverse-event, or tissue retrieval rates between cold and hot techniques; however, the cold approach is preferred because it is time-saving.[156,157] Cold-snare techniques are preferred among the cold techniques because of their higher complete and en-bloc resection rates. Cold-forceps polypectomy should be avoided because of the increased risk of incomplete resection, which ranges from 9% to 61%.[158,159] For diminutive lesions <2 mm, if cold-snare polypectomy is complex, jumbo or large-capacity polypectomy may be considered.[160,161]

There are no uniform guidelines for removing nonpedunculated lesions measuring 10–19 mm. Removal of these lesions with cold-snare or hot-snare polypectomy (with or without mucosal injection) is suggested; however, recent data suggest considering more advanced techniques, such as EMR and ESD, in these patients. EMR has been shown to be a safe and effective method for removing large sessile/serrated polyps. Increasing evidence suggests that using EMR is preferred because of the incomplete resection rate (approximately 31%) and difficulty capturing the lesion when it is removed using conventional polypectomy techniques[162,163] (Figure 4).

For nonpedunculated lesions measuring ≥20 mm, EMR is recommended. The use of contrast agents, such as methylene blue or indigo, helps differentiate submucosa from mucosa and muscularis propria and is recommended. Before the resection, a submucosal injection is administered to facilitate the clear demarcation of layers. It aids in better visualization and decreases damage to the surrounding tissues. Because of easy availability and cost effectiveness, normal saline is commonly used as the injectate along with contrast agents. Normal saline tends to dissipate into surrounding submucosal space, giving the endoscopist a minimal amount of time. Recently, several colloid plasma solutions, such as sodium hyaluronate, 50% dextrose, succinylated gelatin, etc., have been studied.[164,165] The colloidal solution is recommended because it significantly increases the rate of en-bloc resection of the lesion compared with normal saline.[166]

En-bloc resection of lesions measuring <20 mm is usually successful; however, lesions measuring >20 mm typically require piecemeal resection, which is associated with recurrence at the site of EMR. This recurrence rate can vary to as high as 10%–15%, depending on the size of the polyp and whether an en-bloc resection was performed.

Close follow-up of large lesions (≥20 mm) after piecemeal EMR is recommended, with the first surveillance colonoscopy 6 months after index resection. Negative findings on the first surveillance colonoscopy, which include the normal appearance of polyp sites and

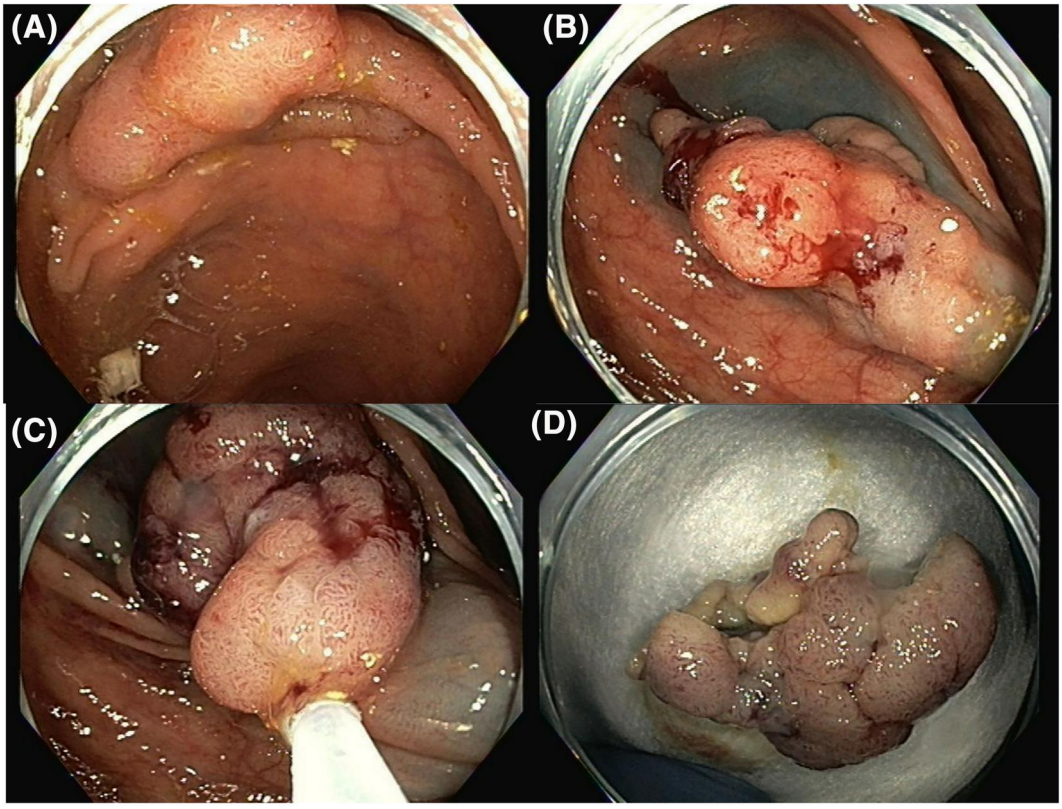

FIGURE 4 Endoscopic mucosal resection of large colon polyp: (A) Large cecal polyp, (B) postsubmucosal lifting, (C) snare resection, (D) resected polyp.

negative scar tissue specimens, are predictive of long-term eradication in 97.9% of cases.[167] Recent guidelines suggest carefully examining the postmucosectomy scar and biopsy of the area to rule out microscopic and macroscopic changes. The area should be examined using dye-based or electronic-based endoscopic image-enhancing techniques. We recommend treatment of a local recurrence on repeat endoscopy according to the most recent US Multi-Society Task Force guidelines.[163]

Inability to lift lesions from the surface decreases the en-bloc resection rate and increases the trauma to nearby tissues. The underlying cause could be submucosal fibrosis secondary to tattooing, previous endoscopic attempts, or lesion invasion into deeper layers.

Newer EMR techniques, such as underwater EMR, have also been studied.[168] In this technique, the lumen is distended with the help of water as opposed to gas, which demarcates the lesion. The step of submucosal injection is bypassed in the technique. In a recent meta-analysis, complete en-bloc resection was successful in 59%, with a pooled recurrence rate and residual adenoma of 5%. Another study demonstrated successful en-bloc resection of 55% of the lesions, of which 79% were verified by histology.[169]

The use of ESD in the colon, although currently limited, is growing, particularly at specialized cancer centers. Because of technical difficulties, ESD is only performed in patients who have a polyp measuring >20 mm that cannot be resected by EMR. ESD can also be used in intramucosal tumors with submucosal fibrosis, sporadic localized tumors (caused by chronic inflammation), and local residual early carcinoma after endoscopic resection.[170] The efficacy and benefits of ESD over EMR are debatable, and conflicting data exist; ESD is less commonly performed in Western countries. A recent meta-analysis showed that ESD had better resection outcomes and less recurrence than EMR; however, further studies are indicated.[171]

For pedunculated lesions measuring ≥10 mm, hot-snare polypectomy is recommended. It is essential to perform en-bloc resections of such polyps to analyze the margins. For pedunculated lesions measuring ≥20 mm or a stalk thickness ≥5 mm, detachable nylon loops or clips should be applied to reduce the risk of post-resection bleeding.[172–175] In a recent meta-analysis, clipping significantly reduced the risk of bleeding after resection of polyps ≥20 mm (7.65% vs. 4.3%; $p < 0.5$) but not for small proximal lesions.[176] Polyp transection should be done in the middle or lower part of the stalk for microscopic analysis. Referral to surgery is recommended for patients who have pedunculated polyps with unfavorable histology, submucosal invasion below the stalk, or extending through the submucosa into deeper layers.[177,178]

Although they are less invasive, endoscopic interventions are associated with adverse effects, depending on the size of the lesion and the modality of intervention. The most common side effect post-polypectomy is bleeding. The risk of bleeding increases with an increase in the size of the polyp (≥10 mm), location of the polyp (right more than left), pedunculated lesions with thick stalks, use of anticoagulation, and various patient comorbidities.[179] Damage to the entire wall of the intestine because of electrocautery can lead to

postpolypectomy coagulation syndrome. Although rare (in 0.08% of patients), perforation is a severe and life-threatening complication of polypectomy.[180]

It is strongly recommended to demarcate the lesion using a tattoo mark for future procedures. When the lesions can be easily identified based on anatomic landmarks, such as in the low rectum, ileocecal valve, or cecum, tattooing is unnecessary. There are no guidelines regarding the localization of tattoos; therefore, it is suggested to have institutional guidelines. If the plan is for future endoscopic resection, injecting the ink at two or three separate sites 3–5 cm distal (anal side) to the lesion is recommended.[181] Conversely, if the lesion is being marked for surgical resection, the tattoo should be targeted in line with the lesion and the opposite lumen wall from the lesion for better visualization. Capturing the tattoo picture with regard to the lesion endoscopically and documenting also helps in easy future detection.

Endoscopy in the management of malignant colonic obstruction

Approximately 75% of malignant colonic obstructions are secondary to colonic adenocarcinoma, with the majority localizing to the left side of the colon.[182] Other causes include metastatic diseases to the colon, uncommon primary colon cancer, or pelvic tumors. Malignant colonic obstruction can be treated either surgically or endoscopically. Usually, at the time of presentation, such patients are not candidates for surgery and have a mortality rate of 10%, with morbidity as high as 45%.[183] Endoscopic alternatives include tumor ablation and placement of either decompression tubes or SEMS.[184] Such patients should be treated using a multidisciplinary approach and should be closely monitored.

Tumor debulking is usually done by endoscopic laser therapy, APC, and snare polypectomy with or without APC.[185–188] High-powered diode laser therapy is preferred over Nd:YAG laser because the equipment is cheaper, compact, and portable for patients who have inoperable CRC.[82] Introduced in the early 1990s, SEMS can be used as a bridge to surgery and can alleviate the risks of emergent surgery.[189] Multiple studies recently have established the benefits of using stents as a bridge to surgery compared with emergent surgery.[189,190] Guidelines published by the European Society for Gastrointestinal Endoscopy recommend that stenting as a bridge to surgery should be discussed as a treatment option in a multidisciplinary manner, a recommendation based on high-quality evidence demonstrating decreased permanent stoma rates and increased rates of single-stage laparoscopic surgery.[191] A recent study showed increased tumor cell dissemination after the placement of SEMS, a topic that remains debatable.[192,193]

A recent meta-analysis published in 2019 studied the long-term outcomes of SEMS and concluded that there was no significant difference in 5-year survival rates between patients who underwent stent placement as a bridge to surgery versus patients who underwent emergent surgery (62.6% vs. 57.2%, respectively; $p = 0.67$).[91] There also were no significant differences in the rates of local recurrence and overall recurrence between the groups. SEMS is increasingly used as a palliative measure in patients who are not candidates for surgery.[92]

In addition to the complications of endoscopy, SEMS placement is associated risks of perforation, stent migration, stent occlusion, and tumor metastasis. In addition, the risk of perforation is increased when dilation is performed after stent placement and thus should be avoided.[194] Transanal colonic decompression is another alternative to diverting colostomy. Successful placement of SEMS can reduce the rate of emergency surgery from 93% to 40%.[195]

Take-home points

- Endoscopy and biopsies are the gold standard for diagnosing colon cancer.
- Endoscopic tattoo placement is recommended if there is a high suspicion for malignancy during index colonoscopy or within 2 weeks after pathology is confirmed.
- EUS and MRI have comparable diagnostic accuracy for staging rectal cancer; the latter is generally preferred because it obviates the need for sedation and provides better locoregional staging accuracy.
- Endoscopic resection is the mainstay of treatment for large colon polyps.
- EMR is the most preferred modality, with ESD reserved for selected cases.
- Colonic stent placement is an effective treatment for malignant colonic obstruction.

BILIARY NEOPLASIA

Patients who have biliary neoplasia may present with jaundice, abdominal pain, anorexia, weight loss, abnormal imaging studies, or elevated serum chemistries. In the serum chemistries, the elevation of bilirubin and alkaline phosphatase levels suggests biliary obstruction. Once there is a suspicion of biliary neoplasia, further testing should be done to accurately stage the cancers and decide on a management plan. A CT scan or MRI may also assist in diagnosis, staging, and therapeutic planning. Tumor markers, including carbohydrate antigen (CA 19-9) and carcinoembryonic antigen (CEA), should be measured, although their role is controversial.[196,197]

Ampullary adenocarcinoma

Primary ampullary tumors are rare (4–10 per million population) but are responsible for 20% of all cancer-related obstructions of the

common bile duct.[198–200] Most of these tumors are detected in the sixth to eighth decades of life because of their initial relatively silent course.[201] Commonly, these tumors are sporadic, with some genetic predisposition. Ampullary carcinomas, including adenocarcinoma, arise from ampullary adenomas by the adenoma–carcinoma sequence, as observed in CRC.[202] Because of increased endoscopic screening in patients with high suspicion, there is an increased in the rate of detection and in the detection of lesions at an early stage, when they are amenable to endoscopic resection.[203] The diagnosis is either made based on incidental findings or because patients present with obstructive jaundice, prompting further evaluation. Approximately 80% of patients present with obstructive jaundice.[204,205] Other symptoms may include diarrhea, blood in stool, microcytic anemia, weight loss, and fatigue. Unlike pancreatic or biliary disease, patients with ampullary adenocarcinoma commonly have recurrent cholangitis because of distal bile duct obstruction. Large lesions can also cause gastric outlet obstruction, in which case patients usually present with nausea and vomiting.

Transabdominal ultrasound (TUS) is usually the first imaging modality performed to evaluate a patient with jaundice. It helps in the detection of intrahepatic or extrahepatic bile duct dilatation and gallstones.[206] In a recent study, only 10 of 127 ampullary masses were detected by ultrasound.[207] In addition, the accuracy for tumor detection is as low as 15%; therefore, it is recommended to order additional imaging as the subsequent diagnostic procedure if no clear etiology is detected on TUS.[207] Patients should undergo imaging modalities, including CT, MRI, and magnetic resonance cholangiopancreatography (MRCP), that are more useful in detecting the lesions and staging of advanced disease.[208,209]

Compared with TUS, CT is more sensitive and accurate in diagnosing masses obstructing the distal common bile duct, but the overall accuracy is still low (20%).[206] In addition to not being sensitive in detecting small ampullary neoplasm, it is not the best modality to determine the degree of tumor invasion into the adjacent tissues or vascular involvement caused by a lack of spatial resolution.[210,211] The role of CT scanning is limited to the diagnosis and evaluation of metastasis. If the malignant obstruction is suspected, it is recommended that patients undergo endoscopic retrograde cholangiopancreatography (ERCP). This helps with better visualization, biopsy for histologic diagnosis, and stent placement when feasible. Similar to CT, ERCP is also not a good choice of imaging modality for preoperative staging. Procuring the tissue at least 48 hours after sphincterotomy (or before sphincterotomy), performing multiple biopsies, and using polymerase chain reaction or immunohistochemical staining to detect p53 or K-ras mutations may help enhance the accuracy of the endoscopic biopsy.[212–216] MRCP may be performed before proceeding with an ERCP. Percutaneous transhepatic cholangiography (PTC) can be performed in patients who have contraindications or technical difficulties for undergoing ERCP.

Although EUS does not help confirm dilatation of the biliary system or staging, it is superior in detecting small ampullary lesions.[217] EUS may have some role in preoperative staging, and it should routinely be performed in such patients. It is the most accurate modality for T staging, with accuracy anywhere between 70% and 90%.[218–223] The accuracy was noted to decrease from 84% to 72% in the presence of a transpapillary endobiliary stent, mostly in T2/T3 tumors.[219] EUS has low sensitivity for N staging, with sensitivity between 21% and 69%.[132,224–226] Therefore, it does not accurately detect distant metastasis, and spiral CT can be combined with EUS.

ERCP is preferred over EUS for patients who require therapeutic intervention. When malignancy is suspected, FNA of the ampulla, papilla, and surrounding deeper structures, including lymph nodes, is recommended.[220,227,228] According to a recent retrospective analysis, EUS-FNA is sensitive (82.4%), specific (100%), and accurate (88.8%) in assessing primary ampullary masses.[229] High accuracy of T staging by EUS helps in avoiding more aggressive and intensive treatments.

NBI helps in the visualization of abnormal vessels and is still under investigation for ampullary masses.[230] Some ampullary cancers may have elevated levels of CA 19-9 and/or CEA, but no specific tumor markers are available. If CA 19-9 and/or CEA levels are elevated, the levels can be serially monitored posttreatment.[231,232]

Endoscopic ampullectomy has been the management of choice for patients with ampullary adenomas or early carcinomas. EUS accurately stages localized disease, thereby avoiding invasive procedures like pancreaticoduodenectomy, which is the treatment of choice in advanced tumors.[218] Robot-assisted transduodenal resection for advanced tumors without significant depth of invasion is performed in select centers but relies on the expertise of the surgeons offering this approach. After the accurate diagnosis and staging of ampullary tumors, further management is similar to that of adenocarcinoma of the pancreas.[233]

Biliary duct neoplasia

Cholangiocarcinoma

Cholangiocarcinoma (CCA) is cancer that originates from the epithelium of bile ducts and the biliary tree (intrahepatic, perihilar, or distal extrahepatic), exclusive of the gallbladder and the ampulla of Vater.[234–236] Based on the origin of the cancer, CCAs are divided into intrahepatic and extrahepatic. Intrahepatic CCAs comprise 20% of all CCAs.[237] They can originate from either small intrahepatic ductules (peripheral CCAs) or large intrahepatic ducts proximal to the bifurcation of the right and left hepatic ducts. Extrahepatic CCAs are further divided into perihilar (60%–70%) and distal.[234] Depending on the extent of involvement of the hepatic ducts, perihilar CCAs are classified into various types using the Bismuth–Corlette classification (see Figure 5).[238,239] The lesions are classified as type I if the tumor originates below the confluence of the left and right hepatic ducts, type II it reaches the junction, type III if the cancer is occluding the common hepatic and the right (IIIa) or left (IIIb) hepatic duct, and type IV if cancer involves the confluence and both ducts or is multicentric. The clinical presentation depends on the location of the lesion. No significant difference is noted in the distribution according to age, sex, race, or

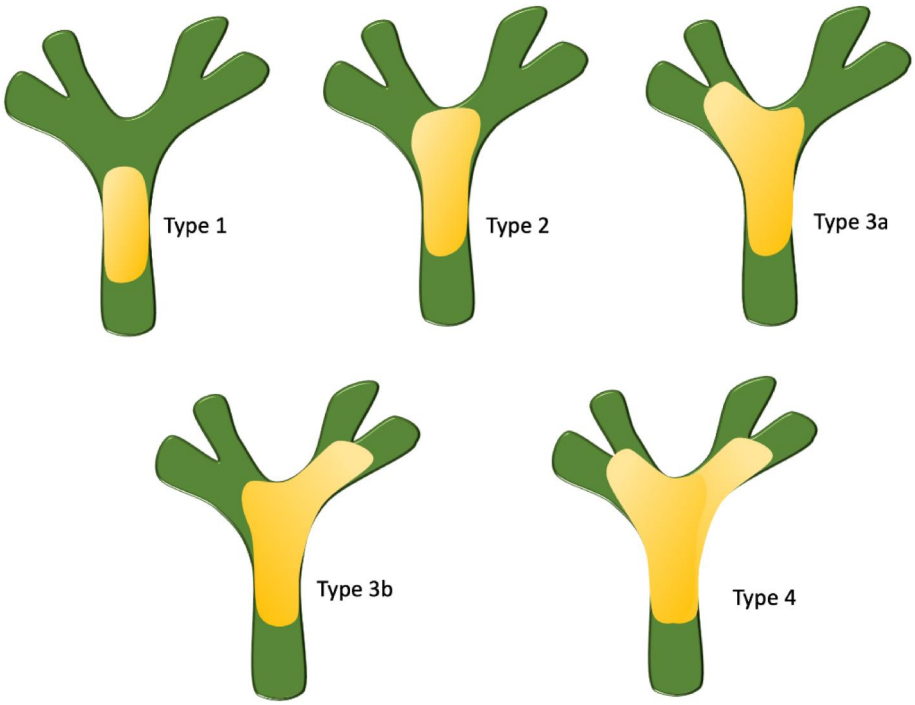

FIGURE 5 Bismuth classification.

associated disease among patients with intrahepatic CCA.[240] Extrahepatic CCA usually presents with symptoms related to obstruction of the biliary system and other common symptoms, including abdominal pain, weight loss, and fever.[240–242] Patients who have intrahepatic lesions usually present with dull epigastric pain, weight loss, and elevated alkaline phosphatase.

Radiologic findings

Localizing and staging lesions in patients who have suspected clinical or radiographic findings are essential because they alter patient management. Patients who present with jaundice are initially worked up with TUS, which can help estimate the size and localization of obstruction and can exclude gallstones.[243] If no apparent cause of jaundice is detected on TUS, such patients should undergo additional testing with CT or MRI. In a minority of cases, CCA is suspected based on elevated tumor markers, including CA 19-9, in which case contrast-enhanced MRI/MRCP or a multiphasic, contrast-enhanced, multidetector-row CT is preferred. Small extrahepatic tumors may not be easily visualized on imaging, in which case bile duct dilatation in the absence of stones is an indirect indicator of suspicion of malignancy.[243] Intrahepatic tumors can be visualized as a mass-forming type, infiltration of the periductal region with associated intrahepatic ductal dilatation, and a mixed type.[235]

Bismuth calcification is also used in determining the tumor resectability and type of surgery. Although TUS and CT can suggest CCA, MRCP has additional advantages. It helps in better visualization of the bile ducts both above and below a stricture and vascular structures. It provides information regarding disease extent and resectability, comparable to CT and MR cholangiography.[244–248] Features like stricture length >10 mm, irregular margins, and shouldering on MRCP suggest malignancy.[249] MRCP has a sensitivity of 77%–86% and a specificity of 63%–98% for diagnosing malignant biliary obstructions caused by CCA.[248,250] MRCP is routinely obtained as a workup for malignancy before performing an ERCP to delineate biliary anatomy.

Role of endoscopy

Endoscopic retrograde cholangiopancreatography

Cholangiography is the visualization of bile ducts after injecting dye, which can be done either endoscopically (ERCP) or percutaneously. Currently, because less invasive studies are accurately identifying pathologies, the use of cholangiography is limited. It is usually used in patients who require preoperative drainage of the biliary tree or have a suspected distal obstruction.[251] If there is suspicion of complete distal obstruction of bile ducts, PTC is preferred over ERCP, although only after ERCP is unsuccessful.

ERCP and PTC also aid in histologic diagnosis when brushings for cytology and biopsy samples can be obtained for diagnosis. However, the diagnostic yield is fairly limited, with a sensitivity of 35%–69%.[213] The sensitivity increases modestly to 43%–88% with the addition of endoscopic biopsy of malignant strictures.[252] Newer tests, such as digital imaging analysis, fluorescence in situ hybridization, and DNA ploidy, may offer increased sensitivity while maintaining the high

specificity of cytology.[253,254] Measurement of tumor markers with brush cytology may provide better diagnostic accuracy with reported sensitivity and specificity of 88% and 97%, respectively.[255]

For Bismuth type I lesions, surgical resection should be considered in medically stable patients without metastatic disease. If the patient is a poor surgical candidate, palliation with metal or plastic stents should be considered. If the level of obstruction is at or above the hilum, extensive injection of contrast should be avoided to decrease the risk of postprocedural cholangitis.[256] MRCP can help define the ductal anatomy before ERCP to reduce the risk of this adverse event.[257] Unilateral endoscopic stent placement is preferred because it has been associated with a relatively lower risk of cholangitis and lower cost, without any difference in success in achieving palliation compared with bilateral stents.[258,259] A study compared air cholangiography with dye cholangiogram and concluded that both methods are equally safe and effective, but air cholangiography was associated with a decreased risk of post-ERCP cholangitis.[260] A recent meta-analysis supported the use of wire-guided cannulation before contrast injection. It was shown to result in greater success of biliary cannulation and a lower risk of post-ERCP pancreatitis.[261,262]

There are two types of biliary stents: plastic and metal. Malfunction of plastic stents is anticipated because they very frequently get occluded by sludge and/or bacterial biofilm, with an average stent patency of 73 days.[263,264] Patients thus may require repeat ERCP very often, so plastic stents are placed only in a select few patients in current clinical practice.

SEMS may be covered or uncovered and remain patent for longer than plastic stents.[265] SEMS are preferred in patients with a life expectancy from >3 to 6 months; however, recent evidence suggests that the choice of the stent should be individualized.[266,267] It is recommended not to perform biliary sphincterotomy before SEMS placement because it may increase the risk of stent migration and other complications, such as bleeding.[268,269] However, a short sphincterotomy can be performed to facilitate advancement of the deployment catheter inside the bile duct. If patients cannot undergo ERCP, stents can be placed by either EUS or PTC.[270] Adverse events associated with ERCP and stent placement include stent occlusion, stent migration, post-ERCP pancreatitis, cholecystitis, cholangitis, luminal perforation, and bleeding.[271]

Another emerging option for the palliative treatment of locally advanced, unresectable, or recurrent extrahepatic CCA and biliary obstruction is PDT, with stent placement over stenting alone when possible. However, the technique is relatively new and is not available at many centers. The earlier studies with PDT showed it as an effective and safe modality with increased survival, warranting randomized controlled trials after that.[272–275] A randomized controlled trial subsequently showed improved survival in patients who underwent PDT with stenting compared with stenting alone (median survival, 493 vs. 98 days; $p < .0001$).[276] Another metanalysis confirmed the above findings. In addition, trials demonstrated improved biliary drainage and better quality of life.[277] Retrospective comparisons of PDT with surgical palliation, stenting alone, and chemotherapy demonstrated survival benefits.[273,278] It is also being used as neoadjuvant therapy for down-staging hilar CCAs to allow surgical resection.[279] Preoperative PDT may improve the negative margin rate of resected malignant strictures.[280] The main complications of PDT are cholangitis and liver abscess; other side effects include phototoxicity.[281]

Cholangioscopy

Cholangioscopy is the direct visualization of the bile ducts using a very thin scope. It is not a common procedure and is used to evaluate biliary strictures that cannot be diagnosed with sampling techniques, such as brush cytology or biopsy[282–286] (Figure 6). Additional advantages include access for targeted biopsies of bile duct lesions, further evaluation of equivocal findings during ERCP, and assessment of the extent of CCA before surgery. It also helps in the extraction of stones for patients who have failed standard ERCP stone-removal techniques. The findings during cholangioscopy suggestive of CCA include visualization of tumor vessels, intraductal nodules, or masses; infiltrative or ulcerated strictures; and papillary and villous mucosal projections.[287] Cholangioscopy reportedly has significantly increased the ability to distinguish between malignant and benign lesions in

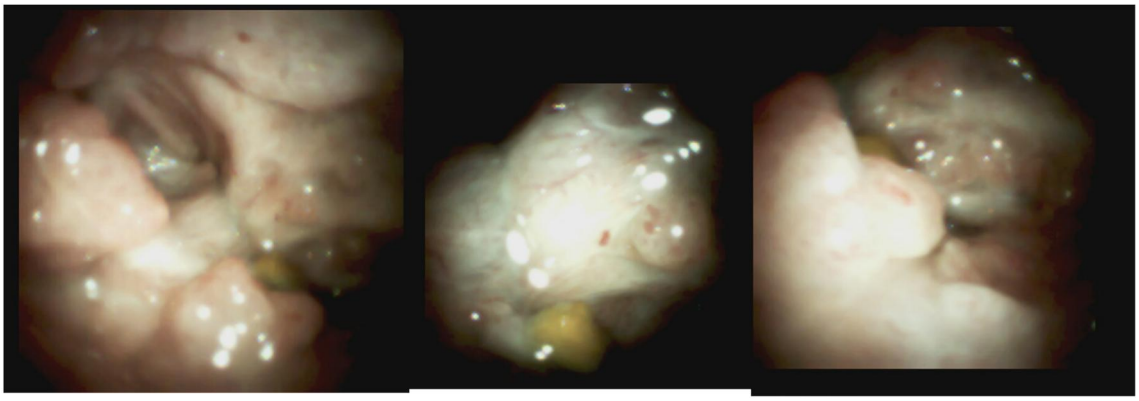

FIGURE 6 Endoscopic retrograde cholangiopancreatography for hilar stricture: Cholangioscopy images revealed a bile duct mass; biopsies were consistent with adenocarcinoma.

patients who have primary sclerosing cholangitis compared with ERCP. The reported sensitivity and specificity of cholangioscopy in biopsies were approximately 92% and 93%, respectively.[284] However, contradictory results have been reported, thus further studies are indicated to establish the role.[283] The downside of cholangioscopy is the increased risk of cholangitis in patients undergoing ERCP with cholangioscopy compared with ERCP alone.[288–290]

Endoscopic ultrasound

Although MRCP and ERCP are the primary modalities for diagnosing and staging CCA, EUS acts as adjunctive when the modalities discussed above are inconclusive. EUS helps with the visualization of local and distal invasion in patients who have distal bile ducts lesions. EUS-FNA of tumors or lymph nodes helps establish the histologic diagnosis, which is reported to be more sensitive versus ERCP with brushings.[291] The sensitivity and specificity of EUS-FNA for diagnosing extrahepatic CCA is 53%–89%.[292–295] In patients who have inconclusive biopsy samples and brushings obtained with ERCP, DeWitt et al. reported a sensitivity of 77%.[296] EUS-FNA has also been shown to be more accurate than CT or positron emission tomography scans for evaluating lymph node metastasis.[297] EUS along with MRCP was found to be more sensitive and specific for early CCA compared with MRCP alone (sensitivity, 98% vs. 90%; specificity, 90% vs. 80%). Further studies should be done to better understand the role of EUS in early CCA.[298]

Take-home points

- A high degree of clinical suspicion is necessary when diagnosing ampullary or biliary tract malignancies.
- A high-quality imaging modality, such as a CT or MRI, is strongly recommended before performing any endoscopic evaluation.
- EUS has an important role in the evaluation ampullary adenomas and adenocarcinomas with intraductal extension into both the common bile duct and the pancreatic duct before formulating a management plan.
- Endoscopic ampullectomy is the treatment of choice for ampullary adenomas and early adenocarcinomas without intraductal extension.
- When endoscopic resection is not available, ERCP with stent placement for biliary drainage is recommended.
- EUS has a limited role in the diagnosis of CCA and is useful when hilar lymph nodes need to be sampled.
- ERCP with biliary brushings and stent placement plays an important role in the diagnosis of CCA.
- Cholangioscopy with biopsies is recommended, when available, to obtain tissue diagnosis.

PANCREATIC CANCER

Pancreatic cancer is the third most common cause of cancer-related morbidity and mortality in the United States.[299] Most pancreatic neoplasms are pancreatic ductal adenocarcinomas (90%), with acinar cell carcinomas, neuroendocrine tumors (NETS), and pancreaticoblastomas making up the rest. Pancreatic adenocarcinoma is characterized by a poor prognosis and a dismal 5-year survival rate, making it one of the deadliest cancers in the United States.[300]

It is estimated that 62,210 cases of pancreatic cancer will be diagnosed in 2022 in the United States, and approximately 49,830 cancer-related deaths are expected.[6,299] The incidence of pancreatic cancer has also been steadily increasing at a rate of 0.5% to 1% every year; and, by 2030, it is projected to become the second-leading cause of cancer-related mortality in the United States.[300]

Even with improvements in imaging and technology, early diagnosis of pancreatic cancer remains difficult because no effective screening strategies exist. The majority of patients still present with nonspecific symptoms and are often at an advanced stage, which is not amenable to curative surgical resection. Painless jaundice is one of the most common presentations of pancreatic cancer localized to the head of the pancreas but occasionally is localized to the uncinate process and body of the pancreas as well. Therefore, pancreatic cancer instigating jaundice secondary to biliary obstruction is likely to be diagnosed earlier than cancers involving the pancreatic tail and body to some extent.[301]

There has been an improvement, albeit minor, in the 5-year survival rate, which has approached approximately 10% in 2020 up from approximately 5% in 2000, largely attributable to improvements in chemotherapeutic agents.[302]

Risk factors

Most cases of pancreatic cancer cases are sporadic and are not associated with any elevated risk determined by family history or known genetic mutations. The risk of developing pancreatic cancer in the general population is estimated to be approximately 1.6% in their lifetime.[303]

Obesity, smoking, family history, and chronic pancreatitis are some of the important risk factors for the development of pancreatic cancer.[304] Numerous genetic mutations, variants, and cancer syndromes have been identified, which increase the risk of pancreatic cancer (see below).

Most recently, the association of new-onset diabetes with the development of pancreatic cancer has been described.[305] It is noted that approximately 0.85%–1.0% of patients with new-onset diabetes have pancreatic cancer, and increasing glycemia levels may precede diagnosis of pancreatic cancer by 24–36 months.[306] These individuals may have as high as an 8-fold risk of pancreatic cancer. Further research is ongoing in this exciting area.

Endoscopic screening and surveillance

Pancreatic cysts have become an increasingly common incidental finding in the era of improved access and utilization of cross-sectional imaging. A fairly large systematic review and meta-analysis concluded that the reported pooled prevalence of pancreatic cysts may be as high as 8%.[307] Because of such a high prevalence and the finding that some cysts have malignant potential, the appropriate characterization of these cysts once they are discovered is an important aspect for their surveillance.

Surveillance is recommended for cysts based on size, location, and characteristics.[308] High-risk features, such as dilation of pancreatic duct, cyst size >3 cm, and the presence of a mural nodule or solid component, necessitate referral to an expert center for further workup and management.

Currently, consensus guidelines also recommend surveillance of certain high-risk individuals who have an elevated lifetime risk of pancreatic cancer.[309] These include individuals with a family history of pancreatic cancer (individuals with two or more blood relatives affected with pancreatic cancer who have at least one first-degree relative; individuals who have three or more relatives with pancreatic cancer on the same side of the family), patients who have germline mutations irrespective of family history (*CDKN2A* and *STK11* [Peutz–Jegher syndrome]), and patients who have germline mutations in at least one first-degree relative (*BRCA1/2*, *ATM*, *PALB2*, *MLH1*, *MSH2*, and *MSH6*).[305,309,310]

Recommended modalities of surveillance should include an MRI/MRCP with an EUS along with baseline fasting blood glucose or HbA1C at baseline. During follow-up, EUS can be alternated with MRI/MRCP annually along with routine screening for diabetes.[305]

Role of endoscopy in diagnosis of pancreatic cancer

EUS plays a significant role in the diagnosis of pancreatic cancer, with EUS-guided tissue sampling considered the gold standard for obtaining a diagnosis.[301] EUS is useful in the direct visualization of the pancreatic mass, obtaining a definitive histopathologic diagnosis by tissue sampling, evaluating locoregional lymphadenopathy (and sampling if needed), and evaluating vascular involvement of the tumor.

EUS-FNA used to be the standard of care to obtain a diagnosis; however, but with the advent of newer needles, EUS-FNB is now considered the standard technique. EUS-FNB needles procure a larger amount of tissue with well preserved architecture. Multiple studies have compared these two techniques, and EUS-FNB had superior diagnostic yield and required less needle passes. Most recently, it has been shown that a combination of both techniques leads to a significantly high diagnostic yield and is feasible using the same needle[311] (Figure 7).

Role of endoscopy in treatment of pancreatic cancer

ERCP for biliary decompression

Biliary obstruction resulting in painless jaundice is one of the most common presentations of pancreatic head/uncinate tumors. ERCP is the gold standard in relieving biliary obstruction and is also useful in obtaining tissue for cytopathology, both of which can be obtained in the same setting. However, ERCP does not add any further staging information and has little value in pancreatic body/tail cancers.

ERCP is associated with reduced morbidity and mortality and improved patient quality of life compared with percutaneous and surgical biliary decompression.[312] When ERCP is unsuccessful, EUS-guided bile duct access with stent placement is increasingly used as an alternative option with good technical and clinical success.[313,314]

Perioperative ERCP for biliary drainage in the setting of resectable cancer is a controversial topic, and routine postoperative biliary drainage is not recommended because of adverse events from ERCP delaying or complicating potential operative interventions.[315] Preoperative biliary drainage has been shown to improve survival in appropriately selected cases.[315] Biliary drainage should be considered in case of pruritis and cholangitis, patients who have a potential delay in surgical resection, or those who require neoadjuvant chemoradiation.

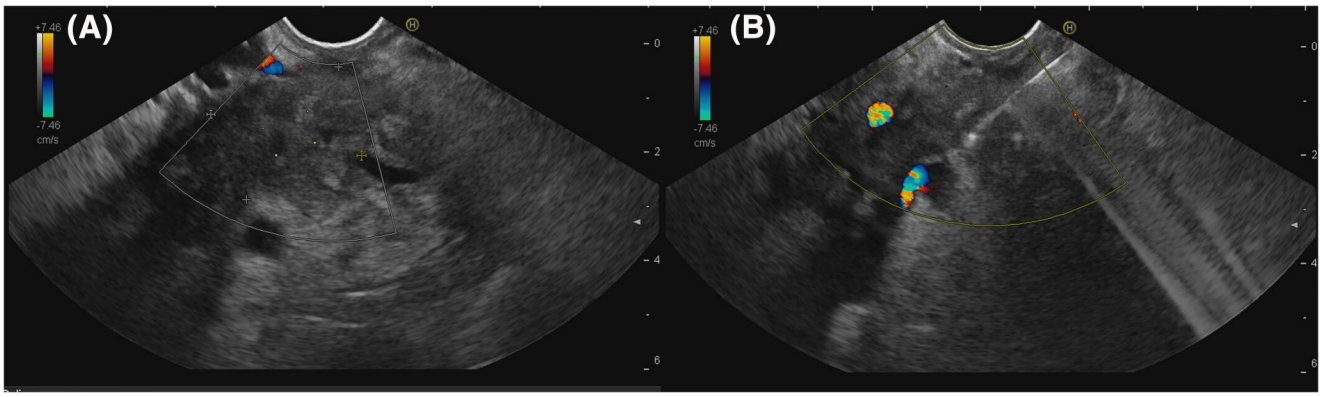

FIGURE 7 Pancreatic head mass fine-needle biopsy: (A) Endoscopic ultrasound image of a pancreatic mass, (B) endoscopic ultrasound-guided fine-needle biopsy.

Plastic stents are usually placed initially when the diagnosis is uncertain, but covered metal stents have been shown to have increased stent patency and are commonly used once a diagnosis and treatment plan is established.

EUS fiducials

Initially, a surgical or percutaneous approach was used for fiducial placement in pancreatic cancer; these have been supplanted in the current era by EUS-guided fiducial placement.[316–318]

The procedure is similar to an EUS-FNA and uses a preloaded, 22-gauge needle. It is a safe procedure and does not require fluoroscopy.[317] It has a high technical success rate and a very low risk of peritoneal seeding.[319] For pancreatic tumors, placement of at least three markers is recommended in different EUS planes.[317,318]

Role of endoscopy in palliation

EUS-guided celiac plexus neurolysis

EUS-guided celiac plexus neurolysis (EUS-CPN) is a procedure that is considered in patients who have pancreatic cancer-related pain. Pain is often a major complaint for patients with pancreatic cancer, and it has been shown that pain severity is associated with decreased survival.[320] In patients who have pain that is refractory to oral therapies, EUS-CPN may be considered. It attempts to ablate the celiac ganglion plexus by the injection of cytolytic agents, such as absolute alcohol or bupivacaine. A recent meta-analysis of 16 studies and 871 patients found that EUS-CPN was effective in reducing pain scores in two thirds of patients with pancreatic cancer by at least 30%.[321]

In patients with newly diagnosed, painful pancreatic cancer, EUS-CPN may be able to reduce pain and analgesia needs based on findings from a double-blind, controlled trial.[322]75 Early adverse effects of EUS-CPN include transient diarrhea, hypotension, and abdominal pain. Reversible or irreversible paralysis, organ injury, and gastric necrosis are among the documented major adverse events of EUS-CPN.

EUS-guided radiofrequency ablation

RFA has been used in recent years for the treatment of pancreatobiliary malignancies with the intent to decrease tumor bulk and possibly enhance immunologic antitumor activity. EUS-RFA has gained traction in recent years as an alternative to percutaneous, surgical, and other endoscopic approaches.[323,324] EUS-RFA of pancreatic tumors has been performed for insulinomas, pancreatic ductal adenocarcinomas, renal cell carcinomas with pancreatic metastases, nonfunctional NETs, as well as intraductal papillary mucinous neoplasms (IPMNs).[325–335] The thermal energy delivered to the tumor may range from 60 to 100°C because temperatures exceeding 100°C increase the risk of adverse events, whereas the benefit derived from such high temperatures likely diminishes because of the immediate vaporization of periprobe tissue, leading to an increase in thermal impedance, which, in turn, can decrease the delivery of ablative energy.[336,337]

The technical success rates in the current published case series range from 70% to 100%.[338] All published case series of pancreatic EUS-RFA to date report a reduction in tumor size and an improvement in symptomatology in most patients. EUS-RFA can lead to the resolution of mural nodules based on prospective, nonrandomized evidence, which reported a 100% resolution rate in 16 branch duct IPMNs.[329] EUS-RFA may also enhance response to palliative chemotherapy and improve survival in unresectable pancreatic cancer; the impact on survival may be most notable among patients who have stage III pancreatic cancer.[339,340] The use of EUS-RFA as a neoadjuvant treatment modality may not be ideal, with a reported downstaging rate of 8% in a retrospective study of 100 patients who had pancreatic ductal adenocarcinoma.[339] In the same study, four of these 100 patients underwent surgical resection after EUS-RFA and chemoradiotherapy; merely one of the four patients was disease free over the study duration, whereas two patients died of disease, and one experienced disease progression. The investigators further noted a prolonged stable disease course, which likely indicates retardation of tumor growth rather than a notable reduction in tumor burden. RFA, RT, and intra-arterial combined with systemic chemotherapy (the triple-approach strategy) may improve survival in patients who have locally advanced pancreatic adenocarcinoma compared with RFA alone.[341] In patients with a simultaneous pancreatobiliary obstruction, EUS-RFA combined with stenting may prolong the duration of stent patency. EUS-RFA may also carry the potential to downstage potentially resectable tumors, allowing patients to undergo curative surgery.[342] None of the studies on the role of EUS-RFA in pancreatic cancer have assessed its impact on patients' quality of life or health-related quality of life.

Postprocedural abdominal pain is the most commonly reported adverse event.[343] Post-RFA pancreatitis is a realistic fear after RFA and can be life-threatening.[326] Prophylactic strategies may mitigate the risk of post-RFA pancreatitis, either by the administration of nonsteroidal anti-inflammatory agents or by deploying a pancreatic duct stent when treating lesions, such as a branch duct IPMN that is in proximity (approximately 2 mm) to the main pancreatic duct. The proximity of the pancreas to the portal venous system, the mesenteric vasculature, the biliary system, and lumens of the stomach, the duodenum, as well as the transverse colon make RFA challenging and theoretically pose a risk of bleeding or thrombosis/thrombophlebitis, biliary injury, and luminal perforation, respectively. In addition, thermal injury could pave the way for bacterial translocation and sepsis after RFA. Prophylactic antibiotics may mitigate the risk of postprocedural sepsis and bacteremia. It is advisable to maintain RFA temperature of 90°C (temperatures >90°

C have been reported to double the risk of thermal injury) and maintain a probe distance of 15 mm from vascular structures to reduce the risk of vascular adverse events.[329,344–346] A distance of 10 mm from luminal structures is also advisable, particularly from the duodenum because duodenal perforations can be notably cumbersome to manage and are associated with significant morbidity.[345,347] The risk of duodenal injury can be further reduced by continuous cooling of the duodenal lumen with infusion saline cooled to 5°C at a rate of 100 ml per minute.[348,349] It is important to highlight the anecdotal and experimental nature of the practices highlighted herein, which simultaneously underscores the importance and need of randomized trials[350] to improve the safety of novel modalities such as EUS-RFA.

Take-home points

- Pancreatic cancer screening should be individualized and based on genetic mutations and/or family history.
- Initial EUS and MRCP, alternating annually, are the recommended modalities for pancreatic cancer screening.
- Pancreatic cyst surveillance depends on the cyst characteristics at the time of cyst detection, with EUS-guided sampling recommended only in the presence of high-risk features.
- Imaging evaluation of solid pancreatic neoplasia should include EUS and a high-quality imaging modality, such as a CT pancreas protocol or MRI, as clinically appropriate.
- EUS has an important role in pancreatic masses and is considered the gold standard to obtain a tissue diagnosis.
- EUS can also help evaluate extension into surrounding vasculature when imaging is equivocal to assess resectability.
- Preoperative ERCP in a patient who has obstructive jaundice caused by a resectable tumor is controversial and is recommended on a case-by-case basis.
- For patients with symptomatic biliary obstruction and unresectable adenocarcinoma of the pancreas, ERCP is recommended as the first-line therapeutic modality to relieve biliary obstruction.
- EUS-guided fiducial placement into pancreatic malignancy is suggested if radiation therapy is planned.
- EUS-guided CPN should be considered in patients with debilitating pancreatic cancer-related pain.
- EUS-guided RFA of unresectable pancreatic cancer is a newer modality that may reduce tumor burden in patients who are not surgical candidates; however, robust evidence is lacking, and the safety profile or EUS-RFA in the pancreas needs to be elucidated.

SMALL BOWEL MALIGNANCIES

Small bowel malignancies are rare, comprising only 3% of GI tract neoplasms and only 0.6% of malignancies in the United States.[351] They are often one of the commonly missed malignancies because of their rarity and their atypical and nonspecific presentation. Annually, small bowel cancer is diagnosed in 11,790 individuals, and approximately 1960 are expected to die from this malignancy. Tumors of the small intestine can be benign or malignant. The benign tumors include adenomas, hamartomas, lipoma, leiomyoma, and fibromas; and the malignant tumors include adenocarcinoma, GI stromal tumors, lymphoma, and metastatic cancer.[352] In the past, adenocarcinomas were the most common malignant tumors of the small bowel. However, according to the National Cancer Database, in the year 2000, the incidence of NETs exceeded the incidence of adenocarcinoma.[353] The overall incidence of small bowel tumors has increased primarily because of the increasing incidence of NETs. Furthermore, the types of tumors that are common vary based on anatomic location; for example, duodenal tumors are commonly adenocarcinomas, and ileal tumors tend to be NETs. Sarcomas and lymphomas can be present anywhere throughout the small intestine.[354] In addition to TNM staging, tumor size and site are independent factors in predicting the prognosis of patients with small bowel malignancies.[355]

Compared with large bowel cancers, small bowel cancers are 13 times less common; however, the incidence of small bowel cancers has been increasing. The mean age of diagnosis is 65 years, and it has a male predominance (1.5:1.0).[356] Analyses from various registries have also shown some racial disparities, with a higher incidence in Black individuals than in White individuals.[356,357] The etiopathogenesis of small bowel cancer is unclear. It is hypothesized that, in addition to genetics, multiple environmental factors, including diet, obesity, and smoking, play a role in malignant transformation of the cells.[358–363] Studies have also shown an increased risk of small bowel cancer in patients with cystic fibrosis; the risk of small bowel malignancies as well as other GI tract malignancies increases even more after lung transplantation.[364] Other risk factors include chronic inflammatory states, including Crohn disease, chronic immunodeficiency states, and autoimmune disorders.[363–366] The symptoms at presentation include, but are not limited to, crampy abdominal pain, weight loss, nausea, vomiting, or GI bleeding.[367–369] Most malignant tumors are symptomatic, unlike benign lesions.[370]

Role of endoscopy in diagnosis of small bowel malignancies

Because of the nonspecific symptoms and rarity of these lesions, diagnosis can be challenging and often is delayed. It has been reported that the approximate delay in diagnosing small intestine tumors is caused by a delay in ordering the appropriate diagnostic study, missed imaging findings, and a delay in patients reporting their

symptoms.[371] Cross-sectional imaging techniques, such as CT or MRI, are able to detect these lesions most of the time.

Endoscopic evaluation is used to obtain an endoscopic view of the lesion in question and to assist in obtaining a tissue diagnosis. The proximal part of the small intestine up to the second or third portion of the duodenum can be evaluated with the help of EGD. A push enteroscopy (using a pediatric colonoscope) can be advanced as far as the proximal jejunum. An EUS does help in accurate T and N staging, but the echoendoscope is limited by its length and its inability to go beyond the duodenum.

Introduced in 2001, the use of wireless video capsule endoscopy in diagnosing small bowel cancer has increased, and it has become a standard approach to evaluating small bowel bleeding.[372–374] However, CT enterography is significantly more sensitive in detecting the lesion than video capsule endoscopy (94% vs. 35%).[375] The disadvantage of video capsule endoscopy is that the lesions in the duodenum and proximal jejunum can be missed because of rapid transit, and samples cannot be taken for tissue diagnosis.

Deep enteroscopy is the most advanced and least invasive technique to allow tissue sampling and therapeutic interventions. Single-balloon enteroscopy, double-balloon enteroscopy (DBE), and spiral enteroscopy are different types of deep bowel enteroscopy. Push enteroscopy allows visualization up to the proximal jejunum with the help of an endoscope using the standard diameter. The drawback of this technique is that it does not permit the visualization of the entire small bowel and is limited to 50–150 cm distal to the ligament of Treitz. Matsumoto et al. compared push enteroscopy versus DBE in a comparative study and found that the length of insertion from the ligament of Treitz was significantly greater for DBE compared with push enteroscopy (median, 92 vs. 22 cm; $p < .0001$) and had a higher diagnostic yield.[376] In addition, spiral enteroscopy had significantly greater depth insertion than push enteroscopy (230 vs. 80 cm; $p < .0001$).[377] Overall, there is no significant difference in diagnostic yield between single-balloon enteroscopy, DBE, and spiral enteroscopy, and the choice of intervention depends on clinical relevance, availability, and physician's comfort.[378]

Endoscopic resection of duodenal polyps

The duodenum is among the most challenging anatomic locations for EMR and ESD. In addition to its thin walls and increased vascularity, the secretion of pancreatic proteolytic enzymes in the duodenum is thought to increase the risk of delayed perforation. Furthermore, managing a duodenal perforation with favorable outcomes can be a challenging endeavor for endoscopists as well as surgeons.[379] These factors are projected appropriately in the recent American Gastroenterology Association clinical practice update, which advises that endoscopic resection in the duodenum, particularly ESD, should be performed only by expert endoscopists.[57]

Duodenal EMR is performed more commonly than ESD. A systematic review of 440 patients (485 polyps) demonstrated that EMR was technically successful in 93% of p0atients.[380] The most common adverse event was bleeding, and luminal perforation was noted in 1% of patients. For locations where accurate snare placement is difficult and for fibrosed lesions (such as those that have been biopsied multiple times), cap-assisted EMR (c-EMR) is preferred.[381] While placing a snare during c-EMR, controlled suction should be applied to avoid full-thickness resection. For fibrosed lesions, placing an over-the-scope clip over the fibrotic area with subsequent EMR of the lesion has also been reported in the literature. Although en-bloc resection is preferable when appropriate, for lesions measuring ≥20 mm, piecemeal EMR is standard practice in most institutions within the United States.[382,383]

Surveillance after duodenal endoscopic resection

No consensus exists on the ideal postresection surveillance strategy for duodenal lesions. A recent retrospective study from a tertiary cancer center reported recurrence in 11 of 66 patients after duodenal EMR.[383] All recurrences were seen in patients who had a tubulovillous adenoma on index EMR; 10 of the 11 patients had undergone piecemeal EMR of the index polyp. Therefore, it is advisable to perform postresection surveillance of nonampullary duodenal adenomas within 3 months of index resection. This should be followed by a second surveillance endoscopy 1 year after resection.

Take-home points

- Small bowel malignancies are rare.
- High clinical suspicion and cross-sectional imaging play key roles in diagnosis.
- Capsule endoscopy is often the first step in endoscopic evaluation.
- Enteroscopy is used when a lesion is identified using noninvasive techniques and there is need to obtain a tissue diagnosis.
- There is no difference between different types of enteroscopy procedures, and availability is institution-dependent/operator-dependent.
- Spiral enteroscopy may increase the risk of luminal perforation and should be performed with caution.
- EMR and ESD in the duodenum are technically challenging and should be performed only by expert endoscopists at high-volume centers.
- Surveillance after endoscopic resection of nonampullary duodenal adenomas is advisable within 3 months of index resection. This should be followed by a second surveillance endoscopy 1 year after resection.

CONCLUSION

In conclusion, endoscopic techniques in their various forms play a key role in screening, surveillance, early detection, diagnosis, treatment, and management of complications of various GI tract cancers. The limitations of endoscopic techniques are gradually diminishing with improvements in technology and devices. The future of cancer prevention, detection, and management is indeed bright.

CONFLICTS OF INTEREST

Nirav Thosani reports personal fees from Covidien LP, AbbVie, Ambu Inc., Medtronic, Boston Scientific Corporation, and PENTAX of America, Inc., outside the submitted work. Vaibhav Wadhwa, Nicole Patel, Dheera Grover, and Faisal S. Ali made no disclosures.

ORCID

Vaibhav Wadhwa https://orcid.org/0000-0002-4019-2110

REFERENCES

1. Siegel RL, Miller KD, Fuchs HE, Jemal A. Cancer statistics, 2022. *CA Cancer J Clin*. 2022;72(1):7-33. doi:10.3322/caac.21708
2. Arnold M, Abnet CC, Neale RE, et al. Global burden of 5 major types of gastrointestinal cancer. *Gastroenterology*. 2020;159(1):335-349.e15. doi:10.1053/j.gastro.2020.02.068
3. Sung H, Ferlay J, Siegel RL, et al. Global cancer statistics 2020: GLOBOCAN estimates of incidence and mortality worldwide for 36 cancers in 185 countries. *CA Cancer J Clin*. 2021;71(3):209-249. doi:10.3322/caac.21660
4. Surveillance, Epidemiology, and End Results Program; National Cancer Institute. Cancer Stat Facts: Esophageal Cancer. Accessed April 9, 2022. https://seer.cancer.gov/statfacts/html/esoph.html
5. Patel N, Benipal B. Incidence of esophageal cancer in the United States from 2001-2015: a United States cancer statistics analysis of 50 states. *Cureus*. 2018;10(12):e3709. doi:10.7759/cureus.3709
6. Siegel RL, Miller KD, Fuchs HE, Jemal A. Cancer statistics, 2022. *CA Cancer J Clin*. 2022;72(1):7-33. doi:10.3322/caac.21708
7. Ashktorab H, Nouri Z, Nouraie M, et al. Esophageal carcinoma in African Americans: a five-decade experience. *Dig Dis Sci*. 2011;56(12):3577-3582. doi:10.1007/S10620-011-1853-1
8. Arnal MJD, Arenas AF, Arbeloa AL. Esophageal cancer: risk factors, screening and endoscopic treatment in Western and Eastern countries. *World J Gastroenterol*. 2015;21(26):7933-7943. doi:10.3748/wjg.v21.i26.7933
9. Blot WJ, Tarone RE. Esophageal cancer. In: Thun MJ, ed. *Schottenfeld and Fraumeni Cancer Epidemiology and Prevention*. 4th ed. Oxford University Press; 2018:579-592. doi:10.1093/oso/9780190238667.003.0030
10. Pohl H, Wrobel K, Bojarski C, et al. Risk factors in the development of esophageal adenocarcinoma. *Am J Gastroenterol*. 2013;108(2):200-207. doi:10.1038/ajg.2012.387
11. Cook MB, Corley DA, Murray LJ, et al. Gastroesophageal reflux in relation to adenocarcinomas of the esophagus: a pooled analysis from the Barrett's and Esophageal Adenocarcinoma Consortium (BEACON). *PLoS One*. 2014;9(7):e103508. doi:10.1371/journal.pone.0103508
12. Qumseya BJ, Bukannan A, Gendy S, et al. Systematic review and meta-analysis of prevalence and risk factors for Barrett's esophagus. *Gastrointest Endosc*. 2019;90(5):707-717.e1. doi:10.1016/j.gie.2019.05.030
13. Marques de Sa I, Marcos P, Sharma P, Dinis-Ribeiro M. The global prevalence of Barrett's esophagus: a systematic review of the published literature. *United Eur Gastroenterol J*. 2020;8(9):1086-1105. doi:10.1177/2050640620939376
14. Krishnamoorthi R, Singh S, Ragunathan K, et al. Factors associated with progression of Barrett's esophagus: a systematic review and meta-analysis. *Clin Gastroenterol Hepatol*. 2018;16(7):1046-1055.e8. doi:10.1016/j.cgh.2017.11.044
15. Bhat S, Coleman HG, Yousef F, et al. Risk of malignant progression in Barrett's esophagus patients: results from a large population-based study. *J Natl Cancer Inst*. 2011;103(13):1049-1057. doi:10.1093/jnci/djr203
16. Hvid-Jensen F, Pedersen L, Drewes AM, Sorensen HT, Funch-Jensen P. Incidence of adenocarcinoma among patients with Barrett's esophagus. *N Engl J Med*. 2011;365(15):1375-1383. doi:10.1056/nejmoa1103042
17. Shaheen NJ, Falk GW, Iyer PG, et al. Diagnosis and management of Barrett's esophagus: an updated ACG guideline. *Am J Gastroenterol*. 2022;117(4):559-587. doi:10.14309/AJG.0000000000001680
18. Shaheen NJ, Falk GW, Iyer PG, et al. Diagnosis and management of Barrett's esophagus: an updated ACG guideline. *Am J Gastroenterol*. 2022;117(4):559-587. doi:10.14309/ajg.0000000000001680
19. Coletta M, Sami SS, Nachiappan A, Fraquelli M, Casazza G, Ragunath K. Acetic acid chromoendoscopy for the diagnosis of early neoplasia and specialized intestinal metaplasia in Barrett's esophagus: a meta-analysis. *Gastrointest Endosc*. 2016;83(1):57-67.e1. doi:10.1016/j.gie.2015.07.023
20. Hajelssedig OE, Zorron Cheng Tao Pu L, Thompson JY, et al. Diagnostic accuracy of narrow-band imaging endoscopy with targeted biopsies compared with standard endoscopy with random biopsies in patients with Barrett's esophagus: a systematic review and meta-analysis. *J Gastroenterol Hepatol*. 2021;36(10):2659-2671. doi:10.1111/jgh.15577
21. Suresh Kumar VC, Harne P, Patthipati VS, et al. Wide-area transepithelial sampling in adjunct to forceps biopsy increases the absolute detection rates of Barrett's oesophagus and oesophageal dysplasia: a meta-analysis and systematic review. *BMJ Open Gastroenterol*. 2020;7(1):e000494. doi:10.1136/bmjgast-2020-000494
22. Januszewicz W, Tan WK, Lehovsky K, et al. Safety and acceptability of esophageal Cytosponge cell collection device in a pooled analysis of data from individual patients. *Clin Gastroenterol Hepatol*. 2019;17(4):647-656.e1. doi:10.1016/j.cgh.2018.07.043
23. Fitzgerald RC, di Pietro M, O'Donovan M, et al. Cytosponge-trefoil factor 3 versus usual care to identify Barrett's oesophagus in a primary care setting: a multicentre, pragmatic, randomised controlled trial. *Lancet*. 2020;396(10247):333-344. doi:10.1016/s0140-6736(20)31099-0
24. Graham DY, Schwartz JT, Cain GD, Gyorkey F. Prospective evaluation of biopsy number in the diagnosis of esophageal and gastric carcinoma. *Gastroenterology*. 1982;82(2):228-231. doi:10.1016/0016-5085(82)90009-9
25. Winawer SJ, Sherlock P, Belladonna JA, Melamed M, Beattie EJ. Endoscopic brush cytology in esophageal cancer. *JAMA*. 1975;232(13):1358. doi:10.1001/jama.1975.03250130042020
26. Thosani N, Abu Dayyeh BK, Sharma P, et al. ASGE Technology Committee systematic review and meta-analysis assessing the ASGE Preservation and Incorporation of Valuable Endoscopic Innovations thresholds for adopting real-time imaging-assisted endoscopic targeted biopsy during endoscopic surveillance of Barrett's esophagus. *Gastrointest Endosc*. 2016;83(4):684-698.e7. doi:10.1016/j.gie.2016.01.007
27. Ajani JA, D'Amico TA, Bentrem DJ, et al. Esophageal and Esophagogastric Junction Cancers, Version 2.2019, NCCN Clinical Practice Guidelines in Oncology. *J Natl Compr Cancer Netw*. 2019;17(7):855-883. doi:10.6004/jnccn.2019.0033

28. Thakkar S, Kaul V. Endoscopic ultrasound staging of esophageal cancer. *Gastroenterol Hepatol (N Y)*. 2020;16(1):14-20.
29. Thosani N, Singh H, Kapadia A, et al. Diagnostic accuracy of EUS in differentiating mucosal versus submucosal invasion of superficial esophageal cancers: a systematic review and meta-analysis. *Gastrointest Endosc*. 2012;75(2):242-253. doi:10.1016/j.gie.2011.09.016
30. DaVee T, Ajani JA, Lee JH. Is endoscopic ultrasound examination necessary in the management of esophageal cancer? *World J Gastroenterol*. 2017;23(5):751. doi:10.3748/wjg.v23.i5.751
31. Chapman CG, Siddiqui UD. New scopes, new accessories, new stents for interventional endoscopic ultrasound. *Clin Endosc*. 2016;49(1):41-46. doi:10.5946/ce.2016.49.1.41
32. Chemaly M, Scalone O, Durivage G, et al. Miniprobe EUS in the pretherapeutic assessment of early esophageal neoplasia. *Endoscopy*. 2008;40(1):2-6. doi:10.1055/s-2007-966958
33. Lee WC, Lee TH, Jang JY, et al. Staging accuracy of endoscopic ultrasound performed by nonexpert endosonographers in patients with resectable esophageal squamous cell carcinoma: is it possible? *Dis Esophagus*. 2015;28(6):574-578. doi:10.1111/dote.12235
34. Jia R, Luan Q, Wang J, Hou D, Zhao S. Analysis of predictors for lymph node metastasis in patients with superficial esophageal carcinoma. *Gastroenterol Res Pract*. 2016;2016:3797615. doi:10.1155/2016/3797615
35. Kelly S, Harris KM, Berry E, et al. A systematic review of the staging performance of endoscopic ultrasound in gastro-oesophageal carcinoma. *Gut*. 2001;49(4):534-539. doi:10.1136/gut.49.4.534
36. Bhutani MS, Hawes RH, Hoffman BJ. A comparison of the accuracy of echo features during endoscopic ultrasound (EUS) and EUS-guided fine-needle aspiration for diagnosis of malignant lymph node invasion. *Gastrointest Endosc*. 1997;45(6):474-479. doi:10.1016/s0016-5107(97)70176-7
37. van Rossum PSN, Goense L, Meziani J, et al. Endoscopic biopsy and EUS for the detection of pathologic complete response after neoadjuvant chemoradiotherapy in esophageal cancer: a systematic review and meta-analysis. *Gastrointest Endosc*. 2016;83(5):866-879. doi:10.1016/j.gie.2015.11.026
38. Kalaitzakis E, Meenan J. Controversies in the use of endoscopic ultrasound in esophageal cancer staging. *Scand J Gastroenterol*. 2009;44(2):133-144. doi:10.1080/00365520802273066
39. Malik S, Sharma G, Sanaka MR, Thota PN. Role of endoscopic therapy in early esophageal cancer. *World J Gastroenterol*. 2018;24(35):3965-3973. doi:10.3748/wjg.v24.i35.3965
40. Sharma P, Shaheen NJ, Katzka D, Bergman JJGHM. AGA clinical practice update on endoscopic treatment of Barrett's esophagus with dysplasia and/or early cancer: expert review. *Gastroenterology*. 2020;158(3):760-769. doi:10.1053/j.gastro.2019.09.051
41. Bennett C, Vakil N, Bergman J, et al. Consensus statements for management of Barrett's dysplasia and early-stage esophageal adenocarcinoma, based on a Delphi process. *Gastroenterology*. 2012;143(2):336-346. doi:10.1053/j.gastro.2012.04.032
42. Wani S, Early D, Edmundowicz S, Sharma P. Management of high-grade dysplasia and intramucosal adenocarcinoma in Barrett's esophagus. *Clin Gastroenterol Hepatol*. 2012;10(7):704-711. doi:10.1016/j.cgh.2012.03.030
43. Eluri S, Shaheen NJ. Endoscopic eradication therapy in Barrett's esophagus. *Tech Gastrointest Endosc*. 2017;19(3):137-142. doi:10.1016/j.tgie.2017.06.001
44. Bergman JJGHM, Zhang YM, He S, et al. Outcomes from a prospective trial of endoscopic radiofrequency ablation of early squamous cell neoplasia of the esophagus. *Gastrointest Endosc*. 2011;74(6):1181-1190. doi:10.1016/j.gie.2011.05.024
45. Wang WL, Chang IW, Chen CC, et al. A case series on the use of circumferential radiofrequency ablation for early esophageal squamous neoplasias in patients with esophageal varices. *Gastrointest Endosc*. 2017;85(2):322-329. doi:10.1016/j.gie.2016.06.045
46. Chen WC, Wolfsen H. Role of radiofrequency ablation in esophageal squamous dysplasia and early neoplasia. *Gastrointest Endosc*. 2017;85(2):330-331. doi:10.1016/j.gie.2016.08.045
47. Manner H, Rabenstein T, Pech O, et al. Ablation of residual Barrett's epithelium after endoscopic resection: a randomized long-term follow-up study of argon plasma coagulation vs. surveillance (APE study). *Endoscopy*. 2014;46(1):6-12. doi:10.1055/S-0033-1358813
48. Ragunath K, Krasner N, Raman VS, Haqqani MT, Phillips CJ, Cheung I. Endoscopic ablation of dysplastic Barrett's oesophagus comparing argon plasma coagulation and photodynamic therapy: a randomized prospective trial assessing efficacy and cost-effectiveness. *Scand J Gastroenterol*. 2005;40(7):750-758. doi:10.1080/00365520510015737
49. Leggett CL, Gorospe EC, Wang KK. Endoscopic therapy for Barrett's esophagus and early esophageal adenocarcinoma. *Gastroenterol Clin North Am*. 2013;42(1):175-185. doi:10.1016/j.gtc.2012.11.010
50. Overholt BF, Lightdale CJ, Wang KK, et al. Photodynamic therapy with porfimer sodium for ablation of high-grade dysplasia in Barrett's esophagus: international, partially blinded, randomized phase III trial. *Gastrointest Endosc*. 2005;62(4):488-498. doi:10.1016/j.gie.2005.06.047
51. Tahara K, Tanabe S, Ishido K, et al. Argon plasma coagulation for superficial esophageal squamous-cell carcinoma in high-risk patients. *World J Gastroenterol*. 2012;18(38):5412-5417. doi:10.3748/wjg.v18.i38.5412
52. Saisho K, Tanaka T, Matono S, et al. Argon plasma coagulation for superficial squamous cell carcinoma in the residual esophagus after esophagectomy. *Esophagus*. 2020;17(4):448-455. doi:10.1007/s10388-020-00733-w
53. Shah PM, Gerdes H. Endoscopic options for early stage esophageal cancer. *J Gastrointest Oncol*. 2015;6(1):20-30. doi:10.3978/j.issn.2078-6891.2014.096
54. Westerveld DR, Nguyen K, Banerjee D, et al. Safety and effectiveness of balloon cryoablation for treatment of Barrett's associated neoplasia: systematic review and meta-analysis. *Endosc Int Open*. 2020;08(02):E172-E178. doi:10.1055/a-1067-4520
55. Greenwald BD, Dumot JA, Abrams JA, et al. Endoscopic spray cryotherapy for esophageal cancer: safety and efficacy. *Gastrointest Endosc*. 2010;71(4):686-693. doi:10.1016/j.gie.2010.01.042
56. Chang K, Jackson CS, Vega KJ. Barrett's esophagus: diagnosis, management, and key updates. *Gastroenterol Clin North Am*. 2021;50(4):751-768. doi:10.1016/j.gtc.2021.08.009
57. Draganov PV, Wang AY, Othman MO, Fukami N. AGA Institute clinical practice update: endoscopic submucosal dissection in the United States. *Clin Gastroenterol Hepatol*. 2019;17(1):16-25.e1. doi:10.1016/j.cgh.2018.07.041
58. Guo HM, Zhang XQ, Chen M, Huang SL, Zou XP. Endoscopic submucosal dissection vs endoscopic mucosal resection for superficial esophageal cancer. *World J Gastroenterol*. 2014;20(18):5540-5547. doi:10.3748/wjg.v20.i18.5540
59. Yang D, Draganov PV. Expanding role of third space endoscopy in the management of esophageal diseases. *Curr Treat Options Gastroenterol*. 2018;16(1):41-57. doi:10.1007/s11938-018-0169-z
60. Zhang Y, Ding H, Chen T, et al. Outcomes of endoscopic submucosal dissection vs esophagectomy for T1 esophageal squamous cell carcinoma in a real-world cohort. *Clin Gastroenterol Hepatol*. 2019;17(1):73-81.e3. doi:10.1016/j.cgh.2018.04.038
61. Yin F, Gonzalo DH, Lai J, Liu X. Histopathology of Barrett's esophagus and early-stage esophageal adenocarcinoma: an updated review. *Gastrointest Disord*. 2019;1(1):147-163. doi:10.3390/gidisord1010011

62. Kerdsirichairat T, Shin EJ. Role of endoscopic ultrasonography guided fiducial marker placement in gastrointestinal cancer. *Curr Opin Gastroenterol*. 2020;36(5):402-408. doi:10.1097/mog.0000000000000662
63. Fernandez DC, Hoffe SE, Barthel JS, et al. Stability of endoscopic ultrasound-guided fiducial marker placement for esophageal cancer target delineation and image-guided radiation therapy. *Pract Radiat Oncol*. 2013;3(1):32-39. doi:10.1016/j.prro.2012.02.006
64. MacHiels M, Van Hooft J, Jin P, et al. Endoscopy/EUS-guided fiducial marker placement in patients with esophageal cancer: a comparative analysis of 3 types of markers. *Gastrointest Endosc*. 2015;82(4):641-649. doi:10.1016/j.gie.2015.03.1972
65. Mocanu A, Barla R, Hoara P, Constantinoiu S. Endoscopic palliation of advanced esophageal cancer. *J Med Life*. 2015;8(2):193-201.
66. Parthipun A, Diamantopoulos A, Shaw A, Dourado R, Sabharwal T. Self-expanding metal stents in palliative malignant oesophageal dysplasia. *Ann Palliat Med*. 2014;3(2):92-103. doi:10.3978/j.issn.2224-5820.2014.04.03
67. Kang Y. A review of self-expanding esophageal stents for the palliation therapy of inoperable esophageal malignancies. *Biomed Res Int*. 2019;2019:1-11. doi:10.1155/2019/9265017
68. Wang C, Wei H, Li Y. Comparison of fully-covered vs partially covered self-expanding metallic stents for palliative treatment of inoperable esophageal malignancy: a systematic review and meta-analysis. *BMC Cancer*. 2020;20(1):73. doi:10.1186/s12885-020-6564-6
69. Chen YH, Li SH, Chiu YC, et al. Comparative study of esophageal stent and feeding gastrostomy/jejunostomy for tracheoesophageal fistula caused by esophageal squamous cell carcinoma. *PLoS One*. 2012;7(8):e42766. doi:10.1371/journal.pone.0042766
70. Ahmed O, Ajani JA, Lee JH. Endoscopic management of esophageal cancer. *World J Gastrointest Oncol*. 2019;11(10):830-841. doi:10.4251/wjgo.v11.i10.830
71. Lightdale CJ, Heier SK, Marcon NE, et al. Photodynamic therapy with porfimer sodium versus thermal ablation therapy with Nd:YAG laser for palliation of esophageal cancer: a multicenter randomized trial. *Gastrointest Endosc*. 1995;42(6):507-512. doi:10.1016/s0016-5107(95)70002-1
72. Sadaps M, Bhatt A, Chevalier C, Sohal D, Videtic G, McNamara MJ. A practical guide to the management of dysphagia in patients with metastatic esophageal cancer. *Ann Esophagus*. 2018;1:2. doi:10.21037/aoe.2018.03.01
73. Inoue T, Ishihara R. Photodynamic therapy for esophageal cancer. *Clin Endosc*. 2021;54(4):494-498. doi:10.5946/ce.2020.073
74. Eluri S, Kaul V, Sharma NR, et al. Palliative endoscopic spray cryotherapy to prevent worsening of dysphagia and improve quality of life in esophageal cancer. *J Clin Oncol*. 2021;39(3 suppl):219. doi:10.1200/JCO.2021.39.3_suppl.219
75. Kachaamy T, Prakash R, Kundranda M, et al. Liquid nitrogen spray cryotherapy for dysphagia palliation in patients with inoperable esophageal cancer. *Gastrointest Endosc*. 2018;88(3):447-455. doi:10.1016/j.gie.2018.04.2362
76. Hanada Y, Leggett CL, Iyer PG, Linn B, Mangels-Dick T, Wang KK. Spray cryotherapy prevents need for palliative stenting in patients with esophageal cancer-associated dysphagia. *Dis Esophagus*. 2022;35(1):doab051. doi:10.1093/dote/doab051
77. Surveillance, Epidemiology, and End Results Program; National Cancer Institute. Cancer Stat Facts: Stomach Cancer. Accessed June 30, 2020. https://seer.cancer.gov/statfacts/html/stomach.html
78. Wroblewski LE, Peek RM, Wilson KT. Helicobacter pylori and gastric cancer: factors that modulate disease risk. *Clin Microbiol Rev*. 2010;23(4):713-739. doi:10.1128/cmr.00011-10
79. Yusefi AR, Lankarani KB, Bastani P, Radinmanesh M, Kavosi Z. Risk factors for gastric cancer: a systematic review. *Asian Pac J Cancer Prev*. 2018;19(3):591-603. doi:10.22034/apjcp.2018.19.3.591
80. Altayar O, Davitkov P, Shah SC, et al. AGA technical review on gastric intestinal metaplasia—epidemiology and risk factors. *Gastroenterology*. 2020;158(3):732-744.e16. doi:10.1053/j.gastro.2019.12.002
81. Correa P, Piazuelo MB, Wilson KT. Pathology of gastric intestinal metaplasia: clinical implications. *Am J Gastroenterol*. 2010;105(3):493-498. doi:10.1038/ajg.2009.728
82. Gupta S, Li D, El Serag HB, et al. AGA clinical practice guidelines on management of gastric intestinal metaplasia. *Gastroenterology*. 2020;158(3):693-702. doi:10.1053/j.gastro.2019.12.003
83. ASGE Standards of Practice Committee; Evans JA, Chandrasekhara V, et al. The role of endoscopy in the management of premalignant and malignant conditions of the stomach. *Gastrointest Endosc*. 2015;82(1):1-8. doi:10.1016/j.gie.2015.03.1967
84. Pouw RE, Barret M, Biermann K, et al. Endoscopic tissue sampling—Part 1: upper gastrointestinal and hepatopancreatobiliary tracts. European Society of Gastrointestinal Endoscopy (ESGE) guideline. *Endoscopy*. 2021;53(11):1174-1188. doi:10.1055/a-1611-5091
85. Ye Y, Tan S. Endoscopic ultrasound-guided fine-needle aspiration biopsy for diagnosis of gastric linitis plastica with negative malignant endoscopy biopsies. *Oncol Lett*. 2018;16(4):4915. doi:10.3892/ol.2018.9258
86. Ajani JA, D'Amico TA, Bentrem DJ, et al. Gastric Cancer, Version 2.2022, NCCN Clinical Practice Guidelines in Oncology. *J Natl Compr Canc Netw*. 2022;20(2):167-192. doi:10.6004/jnccn.2022.0008
87. Brierley JD, Gospodarowicz MK, Wittekind C, eds. *TNM Classification of Malignant Tumours*. 8th ed. Wiley-Blackwell; 2016. Accessed April 9, 2022. https://www.wiley.com/en-gb/TNM+Classification+of+Malignant+Tumours%2C+8th+Edition-p-9781119263579
88. Mocellin S, Marchet A, Nitti D. EUS for the staging of gastric cancer: a meta-analysis. *Gastrointest Endosc*. 2011;73(6):1122-1134. doi:10.1016/j.gie.2011.01.030
89. Ungureanu BS, Sacerdotianu VM, Turcu-Stiolica A, Cazacu IM, Saftoiu A. Endoscopic ultrasound vs. computed tomography for gastric cancer staging: a network meta-analysis. *Diagnostics*. 2021;11(1):134. doi:10.3390/diagnostics11010134
90. Ono H, Yao K, Fujishiro M, et al. Guidelines for endoscopic submucosal dissection and endoscopic mucosal resection for early gastric cancer. *Dig Endosc*. 2016;28(1):3-15. doi:10.1111/den.12518
91. Abdelfatah MM, Barakat M, Lee H, et al. The incidence of lymph node metastasis in early gastric cancer according to the expanded criteria in comparison with the absolute criteria of the Japanese Gastric Cancer Association: a systematic review of the literature and meta-analysis. *Gastrointest Endosc*. 2018;87(2):338-347. doi:10.1016/j.gie.2017.09.025
92. Draganov PV, Wang AY, Othman MO, Fukami N. AGA Institute clinical practice update: endoscopic submucosal dissection in the United States. *Clin Gastroenterol Hepatol*. 2019;17(1):16-25.e1. doi:10.1016/j.cgh.2018.07.041
93. Draganov PV, Aihara H, Karasik MS, et al. Endoscopic submucosal dissection in North America: a large prospective multicenter study. *Gastroenterology*. 2021;160(7):2317-2327.e2. doi:10.1053/j.gastro.2021.02.036
94. Khashab M, Bukhari M, Baron T, et al. International multicenter comparative trial of endoscopic ultrasonography-guided gastroenterostomy versus surgical gastrojejunostomy for the treatment of malignant gastric outlet obstruction. *Endosc Int Open*. 2017;5(4):E275-E281. doi:10.1055/s-0043-101695
95. Tringali A, Costa D, Anderloni A, Carrara S, Repici A, Adler DG. Covered versus uncovered metal stents for malignant gastric outlet obstruction: a systematic review and meta-analysis. *Gastrointest Endosc*. 2020;92(6):1153-1163.e9. doi:10.1016/j.gie.2020.06.033
96. McCarty TR, Garg R, Thompson CC, Rustagi T. Efficacy and safety of EUS-guided gastroenterostomy for benign and malignant gastric

outlet obstruction: a systematic review and meta-analysis. *Endosc Int Open*. 2019;7(11):E1474-E1482. doi:10.1055/a-0996-8178
97. El-Shami K, Oeffinger KC, Erb NL, et al. American Cancer Society colorectal cancer survivorship care guidelines. *CA Cancer J Clin*. 2015;65(6):427-455. doi:10.3322/caac.21286
98. Fitzmaurice C, Akinyemiju TF, Al Lami FH, et al. Global, regional, and national cancer incidence, mortality, years of life lost, years lived with disability, and disability-adjusted life-years for 29 cancer groups, 1990 to 2016: a systematic analysis for the Global Burden of Disease Study. *JAMA Oncol*. 2018;4(11):1553-1568. doi:10.1001/jamaoncol.2018.2706
99. Siegel RL, Miller KD, Sauer AG, et al. Colorectal cancer statistics, 2020. *CA Cancer J Clin*. 2020;70(3):145-164. doi:10.3322/caac.21601
100. Siegel RL, Fedewa SA, Anderson WF, et al. Colorectal cancer incidence patterns in the United States, 1974-2013. *J Natl Cancer Inst*. 2017;109(8):djw322. doi:10.1093/jnci/djw322
101. Wang L, Du M, Wang K, et al. Association of ultra-processed food consumption with colorectal cancer risk among men and women: results from three prospective US cohort studies. *BMJ*. 2022;378:e068921. doi:10.1136/bmj-2021-068921
102. Berger NA. Young adult cancer: influence of the obesity pandemic. *Obesity (Silver Spring)*. 2018;26(4):641-650. doi:10.1002/oby.22137
103. Iacopetta B. Are there two sides to colorectal cancer? *Int J Cancer*. 2002;101(5):403-408. doi:10.1002/ijc.10635
104. Surveillance, Epidemiology, and End Results Program; National Cancer Institute. Cancer Stat Facts: Colorectal Cancer. Accessed April 4, 2022. https://seer.cancer.gov/statfacts/html/colorect.html
105. Brenner H, Kloor M, Pox CP. Colorectal cancer. *Lancet*. 2014;383(9927):1490-1502. doi:10.1016/s0140-6736(13)61649-9
106. Liang PS, Chen TY, Giovannucci E. Cigarette smoking and colorectal cancer incidence and mortality: systematic review and meta-analysis. *Int J Cancer*. 2009;124(10):2406-2415. doi:10.1002/ijc.24191
107. Ma Y, Yang Y, Wang F, et al. Obesity and risk of colorectal cancer: a systematic review of prospective studies. *PLoS One*. 2013;8(1):e53916. doi:10.1371/journal.pone.0053916
108. Cai S, Li Y, Ding Y, Chen K, Jin M. Alcohol drinking and the risk of colorectal cancer death: a meta-analysis. *Eur J Cancer Prev*. 2014;23(6):532-539. doi:10.1097/cej.0000000000000076
109. Fedirko V, Tramacere I, Bagnardi V, et al. Alcohol drinking and colorectal cancer risk: an overall and dose-response meta-analysis of published studies. *Ann Oncol*. 2011;22(9):1958-1972. doi:10.1093/annonc/mdq653
110. Boyle T, Keegel T, Bull F, Heyworth J, Fritschi L. Physical activity and risks of proximal and distal colon cancers: a systematic review and meta-analysis. *J Natl Cancer Inst*. 2012;104(20):1548-1561. doi:10.1093/jnci/djs354
111. Bouvard V, Loomis D, Guyton KZ, et al. Carcinogenicity of consumption of red and processed meat. *Lancet Oncol*. 2015;16(16):1599-1600. doi:10.1016/s1470-2045(15)00444-1
112. Farraye FA, Odze RD, Eaden J, Itzkowitz SH. AGA technical review on the diagnosis and management of colorectal neoplasia in inflammatory bowel disease. *Gastroenterology*. 2010;138(2):746-774.e4. doi:10.1053/j.gastro.2009.12.035
113. Itzkowitz SH, Yio X. Inflammation and cancer IV. Colorectal cancer in inflammatory bowel disease: the role of inflammation. *Am J Physiol Gastrointest Liver Physiol*. 2004;287(1):G7-G17. doi:10.1152/ajpgi.00079.2004
114. Ullman TA, Itzkowitz SH. Intestinal inflammation and cancer. *Gastroenterology*. 2011;140(6):1807-1816.e1. doi:10.1053/j.gastro.2011.01.057
115. Eaden J, Abrams K, Ekbom A, Jackson E, Mayberry J. Colorectal cancer prevention in ulcerative colitis: a case-control study. *Aliment Pharmacol Ther*. 2000;14(2):145-153. doi:10.1046/j.1365-2036.2000.00698.x
116. Lu MJ, Qiu XY, Mao XQ, Li XT, Zhang HJ. Systematic review with meta-analysis: thiopurines decrease the risk of colorectal neoplasia in patients with inflammatory bowel disease. *Aliment Pharmacol Ther*. 2018;47(3):318-331. doi:10.1111/apt.14436
117. Alkhayyat M, Abureesh M, Gill A, et al. Lower rates of colorectal cancer in patients with inflammatory bowel disease using anti-TNF therapy. *Inflamm Bowel Dis*. 2021;27(7):1052-1060. doi:10.1093/ibd/izaa252
118. Gianfredi V, Salvatori T, Villarini M, Moretti M, Nucci D, Realdon S. Is dietary fibre truly protective against colon cancer? A systematic review and meta-analysis. *Int J Food Sci Nutr*. 2018;69(8):904-915. doi:10.1080/09637486.2018.1446917
119. Wali RK, Bianchi L, Kupfer S, et al. Prevention of colonic neoplasia with polyethylene glycol: a short term randomized placebo-controlled double-blinded trial. *PLoS One*. 2018;13(4):e0193544. doi:10.1371/journal.pone.0193544
120. Ben S, Du M, Ma G, et al. Vitamin B2 intake reduces the risk for colorectal cancer: a dose-response analysis. *Eur J Nutr*. 2019;58(4):1591-1602. doi:10.1007/s00394-018-1702-5
121. Huang D, Lei S, Wu Y, et al. Additively protective effects of vitamin D and calcium against colorectal adenoma incidence, malignant transformation and progression: a systematic review and meta-analysis. *Clin Nutr*. 2020;39(8):2525-2538. doi:10.1016/j.clnu.2019.11.012
122. Association between dairy product consumption and colorectal cancer risk in adults: a systematic review and meta-analysis of epidemiologic studies. *Adv Nutr*. 2020;11(4):1055-1057. doi:10.1093/advances/nmaa071
123. Wang Y, Chen J, Zhao R, et al. Dose-response meta-analysis of coffee consumption and risk of colorectal adenoma. *Eur J Clin Nutr*. 2020;74(2):297-306. doi:10.1038/s41430-019-0467-0
124. Chan AT, Arber N, Burn J, et al. Aspirin in the chemoprevention of colorectal neoplasia: an overview. *Cancer Prev Res (Phila)*. 2012;5(2):164-178. doi:10.1158/1940-6207.capr-11-0391
125. Nan H, Hutter CM, Lin Y, et al. Association of aspirin and NSAID use with risk of colorectal cancer according to genetic variants. *JAMA*. 2015;313(11):1133-1142. doi:10.1001/jama.2015.1815
126. Chubak J, Whitlock EP, Williams SB, et al. Aspirin for the prevention of cancer incidence and mortality: systematic evidence reviews for the U.S. Preventive Services Task Force. *Ann Intern Med*. 2016;164(12):814-825. doi:10.7326/m15-2117
127. Shaukat A, Kahi CJ, Burke CA, Rabeneck L, Sauer BG, Rex DK. ACG clinical guidelines: colorectal cancer screening 2021. *Am J Gastroenterol*. 2021;116(3):458-479. doi:10.14309/ajg.0000000000001122
128. Benson AB, Venook AP, Al-Hawary MM, et al. Colon Cancer, Version 2.2021, NCCN Clinical Practice Guidelines in Oncology. *J Natl Compr Canc Netw*. 2021;19(3):329-359. doi:10.6004/jnccn.2021.0012
129. Bartels SAL, van Der Zaag ES, Dekker E, Buskens CJ, Bemelman WA. The effect of colonoscopic tattooing on lymph node retrieval and sentinel lymph node mapping. *Gastrointest Endosc*. 2012;76(4):793-800. doi:10.1016/j.gie.2012.05.005
130. Kethu SR, Banerjee S, Desilets D, et al. Endoscopic tattooing. *Gastrointest Endosc*. 2010;72(4):681-685. doi:10.1016/j.gie.2010.06.020
131. Rex DK. The appropriate use and techniques of tattooing in the colon. *Gastroenterol Hepatol (N Y)*. 2018;14(5):314-317.
132. Amin MB, Greene FL, Edge SB, et al. The Eighth Edition AJCC Cancer Staging Manual: continuing to build a bridge from a population-based to a more "personalized" approach to cancer staging. *CA Cancer J Clin*. 2017;67(2):93-99. doi:10.3322/caac.21388

133. Compton CC, Greene FL. The staging of colorectal cancer: 2004 and beyond. *CA Cancer J Clin*. 2004;54(6):295-308. doi:10.3322/canjclin.54.6.295
134. Tong GJ, Zhang GY, Liu J, et al. Comparison of the eighth version of the American Joint Committee on Cancer manual to the seventh version for colorectal cancer: a retrospective review of our data. *World J Clin Oncol*. 2018;9(7):148-161. doi:10.5306/wjco.v9.i7.148
135. Petrelli F, Ghidini M, Cabiddu M, et al. Microsatellite instability and survival in stage II colorectal cancer: a systematic review and meta-analysis. *Anticancer Res*. 2019;39(12):6431-6441. doi:10.21873/anticanres.13857
136. Corleto VD, Zykaj E, Mercantini P, et al. Is colonoscopy sufficient for colorectal cancer surveillance in all HNPCC patients? *World J Gastroenterol*. 2005;11(47):7541-7544. doi:10.3748/wjg.v11.i47.7541
137. Jung SB, Lee HI, Oh HK, Shin IH, Jeon CH. Clinico-pathologic parameters for prediction of microsatellite instability in colorectal cancer. *Cancer Res Treat*. 2012;44(3):179-186. doi:10.4143/crt.2012.44.3.179
138. National Comprehensive Cancer Network. Treatment by Cancer Type. Accessed April 5, 2022. https://www.nccn.org/guidelines/category_1
139. Lee WS, Yun SH, Chun HK, et al. Pulmonary resection for metastases from colorectal cancer: prognostic factors and survival. *Int J Colorectal Dis*. 2007;22(6):699-704. doi:10.1007/s00384-006-0218-2
140. Yoo PS, Lopez-Soler RI, Longo WE, Cha CH. Liver resection for metastatic colorectal cancer in the age of neoadjuvant chemotherapy and bevacizumab. *Clin Colorectal Cancer*. 2006;6(3):202-207. doi:10.3816/ccc.2006.n.036
141. Foster JH. Treatment of metastatic disease of the liver: a skeptic's view. *Semin Liver Dis*. 1984;4(2):170-179. doi:10.1055/S-2008-1040656
142. Adams DH. Sleisenger and Fordtran's Gastrointestinal and Liver Disease. *Gut*. 2007;56(8):1175. doi:10.1136/gut.2007.121533
143. Videtic GMM, Fisher BJ, Perera FE, et al. Preoperative radiation with concurrent 5-fluorouracil continuous infusion for locally advanced unresectable rectal cancer. *Int J Radiat Oncol Biol Phys*. 1998;42(2):319-324. doi:10.1016/s0360-3016(98)00214-4
144. Puli SR, Bechtold ML, Reddy JBK, Choudhary A, Antillon MR, Brugge WR. How good is endoscopic ultrasound in differentiating various T stages of rectal cancer? Meta-analysis and systematic review. *Ann Surg Oncol*. 2009;16(2):254-265. doi:10.1245/s10434-008-0231-5
145. Puli SR, Bechtold ML, Reddy JBK, Choudhary A, Antillon MR. Can endoscopic ultrasound predict early rectal cancers that can be resected endoscopically? A meta-analysis and systematic review. *Dig Dis Sci*. 2010;55(5):1221-1229. doi:10.1007/s10620-009-0862-9
146. Jurgensen C, Teubner A, Habeck JO, Diener F, Scherubl H, Stolzel U. Staging of rectal cancer by EUS: depth of infiltration in T3 cancers is important. *Gastrointest Endosc*. 2011;73(2):325-328. doi:10.1016/j.gie.2010.10.026
147. Chan BPH, Patel R, Mbuagbaw L, Thabane L, Yaghoobi M. EUS versus magnetic resonance imaging in staging rectal adenocarcinoma: a diagnostic test accuracy meta-analysis. *Gastrointest Endosc*. 2019;90(2):196-203.e1. doi:10.1016/j.gie.2019.04.217
148. Bipat S, Glas AS, Slors FJM, Zwinderman AH, Bossuyt PMM, Stoker J. Rectal cancer: local staging and assessment of lymph node involvement with endoluminal US, CT, and MR imaging—a meta-analysis. *Radiology*. 2004;232(3):773-783. doi:10.1148/radiol.2323031368
149. Lahaye MJ, Engelen SME, Nelemans PJ, et al. Imaging for predicting the risk factors—the circumferential resection margin and nodal disease—of local recurrence in rectal cancer: a meta-analysis. *Semin Ultrasound CT MR*. 2005;26(4):259-268. doi:10.1053/j.sult.2005.04.005
150. Brown G, Richards CJ, Newcombe RG, et al. Rectal carcinoma: thin-section MR imaging for staging in 28 patients. *Radiology*. 1999;211(1):215-222. doi:10.1148/radiology.211.1.r99ap35215
151. Kulinna C, Eibel R, Matzek W, et al. Staging of rectal cancer: diagnostic potential of multiplanar reconstructions with MDCT. *AJR Am J Roentgenol*. 2012;183(2):421-427. doi:10.2214/ajr.183.2.1830421
152. Li XT, Zhang XY, Sun YS, Tang L, Cao K. Evaluating rectal tumor staging with magnetic resonance imaging, computed tomography, and endoluminal ultrasound: a meta-analysis. *Medicine (Baltimore)*. 2016;95(44):e5333. doi:10.1097/md.0000000000005333
153. Gao Y, Li J, Ma X, et al. The value of four imaging modalities in diagnosing lymph node involvement in rectal cancer: an overview and adjusted indirect comparison. *Clin Exp Med*. 2019;19(2):225-234. doi:10.1007/s10238-019-00552-z
154. Winawer SJ, Zauber AG, Ho MN, et al. Prevention of colorectal cancer by colonoscopic polypectomy. *N Engl J Med*. 2010;329(27):1977-1981. doi:10.1056/nejm199312303292701
155. Kaltenbach T, Anderson JC, Burke CA, et al. Endoscopic removal of colorectal lesions—recommendations by the US Multi-Society Task Force on Colorectal Cancer. *Gastroenterology*. 2020;158(4):1095-1129. doi:10.1053/j.gastro.2019.12.018
156. Tranquillini CV, Bernardo WM, Brunaldi VO, de Moura ET, Marques SB, de Moura EGH. Best polypectomy technique for small and diminutive colorectal polyps: a systematic review and meta-analysis. *Arq Gastroenterol*. 2018;55(4):358-368. doi:10.1590/s0004-2803.201800000-79
157. Fujiya M, Sato H, Ueno N, et al. Efficacy and adverse events of cold vs hot polypectomy: a meta-analysis. *World J Gastroenterol*. 2016;22(23):5436. doi:10.3748/wjg.v22.i23.5436
158. Uraoka T, Ramberan H, Matsuda T, Fujii T, Yahagi N. Cold polypectomy techniques for diminutive polyps in the colorectum. *Dig Endosc*. 2014;26(suppl 2):98-103. doi:10.1111/den.12252
159. Thoguluva Chandrasekar V, Aziz M, Patel HK, et al. Efficacy and safety of endoscopic resection of sessile serrated polyps 10 mm or larger: a systematic review and meta-analysis. *Clin Gastroenterol Hepatol*. 2020;18(11):2448-2455.e3. doi:10.1016/j.cgh.2019.11.041
160. Efthymiou M, Taylor ACF, Desmond PV, Allen PB, Chen RY. Biopsy forceps is inadequate for the resection of diminutive polyps. *Endoscopy*. 2011;43(4):312-316. doi:10.1055/s-0030-1256086
161. Kim JS, Lee BI, Choi H, et al. Cold snare polypectomy versus cold forceps polypectomy for diminutive and small colorectal polyps: a randomized controlled trial. *Gastrointest Endosc*. 2015;81(3):741-747. doi:10.1016/j.gie.2014.11.048
162. Pohl H, Srivastava A, Bensen SP, et al. Incomplete polyp resection during colonoscopy—results of the complete adenoma resection (CARE) study. *Gastroenterology*. 2013;144(1):74-80.e1. doi:10.1053/j.gastro.2012.09.043
163. Kaltenbach T, Friedland S, Maheshwari A, et al. Short- and long-term outcomes of standardized EMR of nonpolypoid (flat and depressed) colorectal lesions > or = 1 cm (with video). *Gastrointest Endosc*. 2007;65(6):857-865. doi:10.1016/j.gie.2006.11.035
164. Yoshida N, Naito Y, Inada Y, et al. Endoscopic mucosal resection with 0.13% hyaluronic acid solution for colorectal polyps less than 20 mm: a randomized controlled trial. *J Gastroenterol Hepatol*. 2012;27(8):1377-1383. doi:10.1111/j.1440-1746.2012.07166.x
165. Moss A, Bourke MJ, Kwan V, et al. Succinylated gelatin substantially increases en bloc resection size in colonic EMR: a randomized, blinded trial in a porcine model. *Gastrointest Endosc*. 2010;71(3):589-595. doi:10.1016/j.gie.2009.10.033
166. Yandrapu H, Desai M, Siddique S, et al. Normal saline solution versus other viscous solutions for submucosal injection during endoscopic mucosal resection: a systematic review and meta-analysis. *Gastrointest Endosc*. 2017;85(4):693-699. doi:10.1016/j.gie.2016.12.003

167. Khashab M, Eid E, Rusche M, Rex DK. Incidence and predictors of "late" recurrences after endoscopic piecemeal resection of large sessile adenomas. *Gastrointest Endosc*. 2009;70(2):344-349. doi:10.1016/j.gie.2008.10.037
168. Li P, Ma B, Gong S, Zhang X, Li W. Underwater endoscopic mucosal resection for colorectal lesions: a meta-analysis. *Surg Endosc*. 2021;35(6):3003-3013. doi:10.1007/s00464-020-07745-8
169. Binmoeller KF, Hamerski CM, Shah JN, Bhat YM, Kane SD, Garcia-Kennedy R. Attempted underwater en bloc resection for large (2-4 cm) colorectal laterally spreading tumors (with video). *Gastrointest Endosc*. 2015;81(3):713-718. doi:10.1016/j.gie.2014.10.044
170. Tanaka S, Saitoh Y, Matsuda T, et al. Evidence-based clinical practice guidelines for management of colorectal polyps. *J Gastroenterol*. 2015;50(3):252-260. doi:10.1007/s00535-014-1021-4
171. Lim XC, Nistala KRY, Ng CH, et al. Endoscopic submucosal dissection vs endoscopic mucosal resection for colorectal polyps: a meta-analysis and meta-regression with single arm analysis. *World J Gastroenterol*. 2021;27(25):3925-3939. doi:10.3748/wjg.v27.i25.3925
172. Di Giorgio P, De Luca L, Calcagno G, Rivellini G, Mandato M, De Luca B. Detachable snare versus epinephrine injection in the prevention of postpolypectomy bleeding: a randomized and controlled study. *Endoscopy*. 2004;36(10):860-863. doi:10.1055/s-2004-825801
173. Kouklakis G, Mpoumponaris A, Gatopoulou A, Efraimidou E, Manolas K, Lirantzopoulos N. Endoscopic resection of large pedunculated colonic polyps and risk of postpolypectomy bleeding with adrenaline injection versus endoloop and hemoclip: a prospective, randomized study. *Surg Endosc*. 2009;23(12):2732-2737. doi:10.1007/s00464-009-0478-3
174. Luigiano C, Ferrara F, Ghersi S, et al. Endoclip-assisted resection of large pedunculated colorectal polyps: technical aspects and outcome. *Dig Dis Sci*. 2010;55(6):1726-1731. doi:10.1007/s10620-009-0905-2
175. Ji JS, Lee SW, Kim TH, et al. Comparison of prophylactic clip and endoloop application for the prevention of postpolypectomy bleeding in pedunculated colonic polyps: a prospective, randomized, multicenter study. *Endoscopy*. 2014;46(7):598-604. doi:10.1055/s-0034-1365515
176. Spadaccini M, Albeniz E, Pohl H, et al. Prophylactic clipping after colorectal endoscopic resection prevents bleeding of large, proximal polyps: meta-analysis of randomized trials. *Gastroenterology*. 2020;159(1):148-158.e11. doi:10.1053/j.gastro.2020.03.051
177. Nascimbeni R, Burgart LJ, Nivatvongs S, Larson DR. Risk of lymph node metastasis in T1 carcinoma of the colon and rectum. *Dis Colon Rectum*. 2002;45(2):200-206. doi:10.1007/s10350-004-6147-7
178. Muller S, Chesner IM, Egan MJ, et al. Significance of venous and lymphatic invasion in malignant polyps of the colon and rectum. *Gut*. 1989;30(10):1385-1391. doi:10.1136/gut.30.10.1385
179. Buddingh KT, Herngreen T, Haringsma J, et al. Location in the right hemi-colon is an independent risk factor for delayed post-polypectomy hemorrhage: a multi-center case-control study. *Am J Gastroenterol*. 2011;106(6):1119-1124. doi:10.1038/ajg.2010.507
180. Reumkens A, Rondagh EJA, Bakker CM, Winkens B, Masclee AA, Sanduleanu S. Post-colonoscopy complications: a systematic review, time trends, and meta-analysis of population-based studies. *Am J Gastroenterol*. 2016;111(8):1092-1101. doi:10.1038/ajg.2016.234
181. Moss A, Bourke MJ, Pathmanathan N. Safety of colonic tattoo with sterile carbon particle suspension: a proposed guideline with illustrative cases. *Gastrointest Endosc*. 2011;74(1):214-218. doi:10.1016/j.gie.2011.01.056
182. Flynn CL. Surgical management of the acutely obstructed colon. *Am J Surg*. 1990;159(2):269-270. doi:10.1016/s0002-9610(05)80281-8
183. Riedl S, Weibelt H, Bergmann U, Hermanek P Jr. [Postoperative complications and fatalities in surgical therapy of colon carcinoma. Results of the German multicenter study by the Colorectal Carcinoma Study Group]. *Chirug*. 1995;66(6):597-606.
184. Harrison ME, Anderson MA, Appalaneni V, et al. The role of endoscopy in the management of patients with known and suspected colonic obstruction and pseudo-obstruction. *Gastrointest Endosc*. 2010;71(4):669-679. doi:10.1016/j.gie.2009.11.027
185. Mathus-Vliegen EM, Tytgat GN. Analysis of failures and complications of neodymium: YAG laser photocoagulation in gastrointestinal tract tumors. A retrospective survey of 8 years' experience. *Endoscopy*. 1990;22(1):17-23. doi:10.1055/s-2007-1012780
186. Courtney ED, Raja A, Leicester RJ. Eight years' experience of high-powered endoscopic diode laser therapy for palliation of colorectal carcinoma. *Dis Colon Rectum*. 2005;48(4):845-850. doi:10.1007/s10350-004-0833-3
187. Gevers AM, Macken E, Hiele M, Rutgeerts P. Endoscopic laser therapy for palliation of patients with distal colorectal carcinoma: analysis of factors influencing long-term outcome. *Gastrointest Endosc*. 2000;51(5):580-585. doi:10.1016/s0016-5107(00)70294-x
188. Regula J, Wronska E, Polkowski M, et al. Argon plasma coagulation after piecemeal polypectomy of sessile colorectal adenomas: long-term follow-up study. *Endoscopy*. 2003;35(3):212-218. doi:10.1055/S-2003-37254
189. Dohmoto M. New method endoscopic implantation of rectal stent in palliative treatment of malignant stenosis. *Endoscopy Digest*. 1991;3:1507-1512.
190. Sahebally SM, Sarwar A, Cooke F. Short-term outcomes following the use of self-expanding metallic stents in acute malignant colonic obstruction—a single centre experience. *Int J Surg*. 2014;12(11):1198-1202. doi:10.1016/j.ijsu.2014.09.010
191. van Hooft JE, Veld JV, Arnold D, et al. Self-expandable metal stents for obstructing colonic and extracolonic cancer: European Society of Gastrointestinal Endoscopy (ESGE) guideline—update 2020. *Endoscopy*. 2020;52(5):389-407. doi:10.1055/a-1140-3017
192. Maruthachalam K, Lash GE, Shenton BK, Horgan AF. Tumour cell dissemination following endoscopic stent insertion. *Br J Surg*. 2007;94(9):1151-1154. doi:10.1002/bjs.5790
193. Sloothaak DAM, van Den Berg MW, Dijkgraaf MGW, et al. Oncological outcome of malignant colonic obstruction in the Dutch Stent-In 2 trial. *Br J Surg*. 2014;101(13):1751-1757. doi:10.1002/bjs.9645
194. Fisher DA, Maple JT, Ben-Menachem T, et al. Complications of colonoscopy. *Gastrointest Endosc*. 2011;74(4):745-752. doi:10.1016/j.gie.2011.07.025
195. Fischer A, Schrag HJ, Goos M, Obermaier R, Hopt UT, Baier PK. Transanal endoscopic tube decompression of acute colonic obstruction: experience with 51 cases. *Surg Endosc*. 2008;22(3):683-688. doi:10.1007/S00464-007-9461-Z
196. Patel AH, Harnois DM, Klee GG, LaRusso NF, Gores GJ. The utility of CA 19-9 in the diagnoses of cholangiocarcinoma in patients without primary sclerosing cholangitis. *Am J Gastroenterol*. 2000;95(1):204-207. doi:10.1111/j.1572-0241.2000.01685.x
197. Steinberg WM, Gelfand R, Anderson KK, et al. Comparison of the sensitivity and specificity of the CA19-9 and carcinoembryonic antigen assays in detecting cancer of the pancreas. *Gastroenterology*. 1986;90(2):343-349. doi:10.1016/0016-5085(86)90930-3
198. Palazzo L. Staging of ampullary carcinoma by endoscopic ultrasonography. *Endoscopy*. 1998;30(suppl 1):A128-A131. doi:10.1055/S-2007-1001493
199. Van Dyke AL, Shiels MS, Jones GS, et al. Biliary tract cancer incidence and trends in the United States by demographic group, 1999-2013. *Cancer*. 2019;125(9):1489-1498. doi:10.1002/cncr.31942
200. Goodman MT, Yamamoto J. Descriptive study of gallbladder, extrahepatic bile duct, and ampullary cancers in the United States,

1997-2002. *Cancer Causes Control*. 2007;18(4):415-422. doi:10.1007/S10552-006-0109-4
201. Jung MK, Cho CM, Park SY, et al. Endoscopic resection of ampullary neoplasms: a single-center experience. *Surg Endosc*. 2009;23(11):2568-2574. doi:10.1007/S00464-009-0464-9
202. Kadmon M, Tandara A, Herfarth C. Duodenal adenomatosis in familial adenomatous polyposis coli. A review of the literature and results from the Heidelberg Polyposis Register. *Int J Colorectal Dis*. 2001;16(2):63-75. doi:10.1007/S003840100290
203. Li S, Wang Z, Cai F, et al. New experience of endoscopic papillectomy for ampullary neoplasms. *Surg Endosc*. 2019;33(2):612-619. doi:10.1007/S00464-018-6577-2
204. Liu XF, Tang K, Sun FB, Sui LL, Xu G. Partial resection of the pancreatic head and duodenum for management of carcinoma of the ampulla of Vater: a case report. *Anticancer Res*. 2016;36(3):1319-1324.
205. Monson JRT, Donohue JH, McEntee GP, et al. Radical resection for carcinoma of the ampulla of Vater. *Arch Surg*. 1991;126(3):353-357. doi:10.1001/archsurg.1991.01410270099016
206. Skordilis P, Mouzas IA, Dimoulios PD, Alexandrakis G, Moschandrea J, Kouroumalis E. Is endosonography an effective method for detection and local staging of the ampullary carcinoma? A prospective study. *BMC Surg*. 2002;2:1. doi:10.1186/1471-2482-2-1
207. Qiao QL, Zhao YG, Ye ML, et al. Carcinoma of the ampulla of Vater: factors influencing long-term survival of 127 patients with resection. *World J Surg*. 2007;31(1):137-143. doi:10.1007/S00268-006-0213-3
208. Tsukada K, Takada T, Miyazaki M, et al. Diagnosis of biliary tract and ampullary carcinomas. *J Hepatobiliary Pancreat Surg*. 2008;15(1):31-40. doi:10.1007/S00534-007-1278-6
209. Irie H, Honda H, Shinozaki K, et al. MR imaging of ampullary carcinomas. *J Comput Assist Tomogr*. 2002;26(5):711-717. doi:10.1097/00004728-200209000-00008
210. Bakkevold KE, Arnesjo B, Kambestad B. Carcinoma of the pancreas and papilla of Vater: presenting symptoms, signs, and diagnosis related to stage and tumour site. A prospective multicentre trial in 472 patients. Norwegian Pancreatic Cancer Trial. *Scand J Gastroenterol*. 1992;27(4):317-325. doi:10.3109/00365529209000081
211. Rivadeneira DE, Pochapin M, Grobmyer SR, et al. Comparison of linear array endoscopic ultrasound and helical computed tomography for the staging of periampullary malignancies. *Ann Surg Oncol*. 2003;10(8):890-897. doi:10.1245/aso.2003.03.555
212. Bourgeois N, Dunham F, Verhest A, Cremer M. Endoscopic biopsies of the papilla of Vater at the time of endoscopic sphincterotomy: difficulties in interpretation. *Gastrointest Endosc*. 1984;30(3):163-166. doi:10.1016/S0016-5107(84)72357-1
213. Ponchon T, Gagnon P, Berger F, et al. Value of endobiliary brush cytology and biopsies for the diagnosis of malignant bile duct stenosis: results of a prospective study. *Gastrointest Endosc*. 1995;42(6):565-572. doi:10.1016/S0016-5107(95)70012-9
214. Park SH, Kim Y, Park YH, et al. Clinicopathologic correlation of p53 protein overexpression in adenoma and carcinoma of the ampulla of Vater. *World J Surg*. 2000;24(1):54-59. doi:10.1007/S002689910011
215. Takashima M, Ueki T, Nagai E, et al. Carcinoma of the ampulla of Vater associated with or without adenoma: a clinicopathologic analysis of 198 cases with reference to p53 and Ki-67 immunohistochemical expressions. *Mod Pathol*. 2000;13(12):1300-1307. doi:10.1038/modpathol.3880238
216. Younes M, Riley S, Genta RM, Mosharaf BS, Mody DR. p53 protein accumulation in tumors of the ampulla of Vater. *Cancer*. 1995;76(7):1150-1154. doi:10.1002/1097-0142(19951001)76:7<1150::AID-CNCR2820760709>3.0.CO;2-E
217. Chen WX, Xie QG, Zhang WF, et al. Multiple imaging techniques in the diagnosis of ampullary carcinoma. *Hepatobiliary Pancreat Dis Int*. 2008;7(6):649-653.
218. Quirk DM, Rattner DW, Fernandez-Del Castillo C, Warshaw AL, Brugge WR. The use of endoscopic ultrasonography to reduce the cost of treating ampullary tumors. *Gastrointest Endosc*. 1997;46(4):334-337. doi:10.1016/S0016-5107(97)70121-4
219. Cannon ME, Carpenter SL, Elta GH, et al. EUS compared with CT, magnetic resonance imaging, and angiography and the influence of biliary stenting on staging accuracy of ampullary neoplasms. *Gastrointest Endosc*. 1999;50(1):27-33. doi:10.1016/S0016-5107(99)70340-8
220. Rosch T, Braig C, Gain T, et al. Staging of pancreatic and ampullary carcinoma by endoscopic ultrasonography. Comparison with conventional sonography, computed tomography, and angiography. *Gastroenterology*. 1992;102(1):188-199. doi:10.1016/0016-5085(92)91800-J
221. Midwinter MJ, Beveridge CJ, Wilsdon JB, Bennett MK, Baudouin CJ, Charnley RM. Correlation between spiral computed tomography, endoscopic ultrasonography and findings at operation in pancreatic and ampullary tumours. *Br J Surg*. 1999;86(2):189-193. doi:10.1046/J.1365-2168.1999.01042.X
222. Kubo H, Chijiiwa Y, Akahoshi K, Hamada S, Matsui N, Nawata H. Pre-operative staging of ampullary tumours by endoscopic ultrasound. *Br J Radiol*. 1999;72(857):443-447. doi:10.1259/bjr.72.857.10505006
223. Buscall L, Pages P, Berthelemy P, Fourtanier G, Frexinos J, Escourrou J. Role of EUS in the management of pancreatic and ampullary carcinoma: a prospective study assessing resectability and prognosis. *Gastrointest Endosc*. 1999;50(1):34-40. doi:10.1016/S0016-5107(99)70341-X
224. Itoh A, Goto H, Naitoh Y, Hirooka Y, Furukawa T, Hayakawa T. Intraductal ultrasonography in diagnosing tumor extension of cancer of the papilla of Vater. *Gastrointest Endosc*. 1997;45(3):251-260. doi:10.1016/S0016-5107(97)70267-0
225. Tio TL, Sie LH, Kallimanis G, et al. Staging of ampullary and pancreatic carcinoma: comparison between endosonography and surgery. *Gastrointest Endosc*. 1996;44(6):706-713. doi:10.1016/S0016-5107(96)70056-1
226. Shoup M, Hodul P, Aranha GV, et al. Defining a role for endoscopic ultrasound in staging periampullary tumors. *Am J Surg*. 2000;179(6):453-456. doi:10.1016/S0002-9610(00)00379-2
227. Mallery JS, Centeno BA, Hahn PF, Chang YC, Warshaw AL, Brugge WR. Pancreatic tissue sampling guided by EUS, CT/US, and surgery: a comparison of sensitivity and specificity. *Gastrointest Endosc*. 2002;56(2):218-224. doi:10.1016/S0016-5107(02)70181-8
228. Tierney WM, Francis IR, Eckhauser F, Elta G, Nostrant TT, Scheiman JM. The accuracy of EUS and helical CT in the assessment of vascular invasion by peripapillary malignancy. *Gastrointest Endosc*. 2001;53(2):182-188. doi:10.1067/mge.2001.111776
229. DeFrain C, Chang CY, Srikureja W, Nguyen PT, Gu M. Cytologic features and diagnostic pitfalls of primary ampullary tumors by endoscopic ultrasound-guided fine-needle aspiration biopsy. *Cancer*. 2005;105(5):289-297. doi:10.1002/cncr.21306
230. Uchiyama Y, Imazu H, Kakutani H, et al. New approach to diagnosing ampullary tumors by magnifying endoscopy combined with a narrow-band imaging system. *J Gastroenterol*. 2006;41(5):483-490. doi:10.1007/S00535-006-1800-7
231. Smith RA, Ghaneh P, Sutton R, Raraty M, Campbell F, Neoptolemos JP. Prognosis of resected ampullary adenocarcinoma by preoperative serum CA19-9 levels and platelet-lymphocyte ratio. *J Gastrointest Surg*. 2008;12(8):1422-1428. doi:10.1007/S11605-008-0554-3

232. Todoroki T, Koike N, Morishita Y, et al. Patterns and predictors of failure after curative resections of carcinoma of the ampulla of Vater. *Ann Surg Oncol*. 2003;10(10):1176-1183. doi:10.1245/aso.2003.07.512
233. Standards of Practice Committee, Baron TH, Mallery JS, et al. The role of endoscopy in the evaluation and treatment of patients with pancreaticobiliary malignancy. *Gastrointest Endosc*. 2003;58(5):643-649. doi:10.1016/S0016-5107(03)01994-1
234. American Cancer Society. Perihilar Bile Duct Cancer Stages | Perihilar Cholangiocarcinoma Stages. Accessed April 11, 2022. https://www.cancer.org/cancer/bile-duct-cancer/detection-diagnosis-staging/staging/staging-extrahepatic-bile-duct.html
235. American Cancer Society. Intrahepatic Bile Duct Cancer Stages | Intrahepatic Cholangiocarcinoma Stages. Accessed April 11, 2022. https://www.cancer.org/cancer/bile-duct-cancer/detection-diagnosis-staging/staging/staging-intrahepatic-bile-duct.html
236. American Cancer Society. Distal Bile Duct Cancer Stages | Distal Cholangiocarcinoma Stages. Accessed April 11, 2022. https://www.cancer.org/cancer/bile-duct-cancer/detection-diagnosis-staging/staging/staging-distal-extrahepatic-bile-duct.html
237. Saha SK, Zhu AX, Fuchs CS, Brooks GA. Forty-year trends in cholangiocarcinoma incidence in the U.S.: intrahepatic disease on the rise. *Oncologist*. 2016;21(5):594-599. doi:10.1634/theoncologist.2015-0446
238. Bismuth H, Nakache R, Diamond T. Management strategies in resection for hilar cholangiocarcinoma. *Ann Surg*. 1992;215(1):31-38. doi:10.1097/00000658-199201000-00005
239. Vauthey JN, Blumgart LH. Recent advances in the management of cholangiocarcinomas. *Semin Liver Dis*. 1994;14(2):109-114. doi:10.1055/S-2007-1007302
240. Nakeeb A, Pitt HA, Sohn TA, et al. Cholangiocarcinoma. A spectrum of intrahepatic, perihilar, and distal tumors. *Ann Surg*. 1996;224(4):463-475. doi:10.1097/00000658-199610000-00005
241. Nagorney DM, Donohue JH, Farnell MB, Schleck CD, Ilstrup DM. Outcomes after curative resections of cholangiocarcinoma. *Arch Surg*. 1993;128(8):871-878. doi:10.1001/archsurg.1993.01420200045008
242. Blechacz B, Komuta M, Roskams T, Gores GJ. Clinical diagnosis and staging of cholangiocarcinoma. *Nat Rev Gastroenterol Hepatol*. 2011;8(9):512-522. doi:10.1038/nrgastro.2011.131
243. Saini S. Imaging of the hepatobiliary tract. *N Engl J Med*. 2009;336(26):1889-1894. doi:10.1056/nejm199706263362607
244. Fulcher AS, Turner MA. HASTE MR cholangiography in the evaluation of hilar cholangiocarcinoma. *AJR Am J Roentgenol*. 2013;169(6):1501-1505. doi:10.2214/ajr.169.6.9393153
245. Schwartz LH, Coakley FV, Sun Y, Blumgart LH, Fong Y, Panicek DM. Neoplastic pancreaticobiliary duct obstruction: evaluation with breath-hold MR cholangiopancreatography. *AJR Am J Roentgenol*. 1998;170(6):1491-1495. doi:10.2214/ajr.170.6.9609160
246. Zidi SH, Prat F, Le Guen O, Rondeau Y, Pelletier G. Performance characteristics of magnetic resonance cholangiography in the staging of malignant hilar strictures. *Gut*. 2000;46(1):103-106. doi:10.1136/gut.46.1.103
247. Yeh TS, Jan YY, Tseng JH, et al. Malignant perihilar biliary obstruction: magnetic resonance cholangiopancreatographic findings. *Am J Gastroenterol*. 2000;95(2):432-440. doi:10.1111/j.1572-0241.2000.01763.x
248. Rosch T, Meining A, Fruhmorgen S, et al. A prospective comparison of the diagnostic accuracy of ERCP, MRCP, CT, and EUS in biliary strictures. *Gastrointest Endosc*. 2002;55(7):870-876. doi:10.1067/mge.2002.124206
249. Park MS, Kim TK, Kim KW, et al. Differentiation of extrahepatic bile duct cholangiocarcinoma from benign stricture: findings at MRCP versus ERCP. *Radiology*. 2004;233(1):234-240. doi:10.1148/radiol.2331031446
250. Guibaud L, Bret PM, Reinhold C, Atri M, Barkun AN. Bile duct obstruction and choledocholithiasis: diagnosis with MR cholangiography. *Radiology*. 1995;197(1):109-115. doi:10.1148/radiology.197.1.7568807
251. Freeman ML, Sielaff TD. A modern approach to malignant hilar biliary obstruction. *Rev Gastroenterol Disord*. 2003;3(4):187-201.
252. Rustgi AK, Kelsey PB, Guelrud M, Saini S, Schapiro RH. Malignant tumors of the bile ducts: diagnosis by biopsy during endoscopic cannulation. *Gastrointest Endosc*. 1989;35(3):248-251. doi:10.1016/S0016-5107(89)72768-1
253. Moreno Luna LE, Kipp B, Halling KC, et al. Advanced cytologic techniques for the detection of malignant pancreatobiliary strictures. *Gastroenterology*. 2006;131(4):1064-1072. doi:10.1053/j.gastro.2006.08.021
254. Lindberg B, Enochsson L, Tribukait B, Arnelo U, Bergquist A. Diagnostic and prognostic implications of DNA ploidy and S-phase evaluation in the assessment of malignancy in biliary strictures. *Endoscopy*. 2006;38(6):561-565. doi:10.1055/S-2006-925387
255. Siqueira E, Schoen RE, Silverman W, et al. Detecting cholangiocarcinoma in patients with primary sclerosing cholangitis. *Gastrointest Endosc*. 2002;56(1):40-47. doi:10.1067/mge.2002.125105
256. Chang WH, Kortan P, Haber GB. Outcome in patients with bifurcation tumors who undergo unilateral versus bilateral hepatic duct drainage. *Gastrointest Endosc*. 1998;47(5):354-362. doi:10.1016/S0016-5107(98)70218-4
257. Lee SS, Kim MH, Lee SK, et al. MR cholangiography versus cholangioscopy for evaluation of longitudinal extension of hilar cholangiocarcinoma. *Gastrointest Endosc*. 2002;56(1):25-32. doi:10.1067/mge.2002.125363
258. Hintze RE, Abou-Rebyeh H, Adler A, Veltzke-Schlieker W, Felix R, Wiedenmann B. Magnetic resonance cholangiopancreatography-guided unilateral endoscopic stent placement for Klatskin tumors. *Gastrointest Endosc*. 2001;53(1):40-46. doi:10.1067/mge.2001.111388
259. Harewood GC, Baron TH. Cost analysis of magnetic resonance cholangiography in the management of inoperable hilar biliary obstruction. *Am J Gastroenterol*. 2002;97(5):1152-1158. doi:10.1111/j.1572-0241.2002.05682.x
260. Sud R, Puri R, Choudhary NS, Mehta A, Jain PK. Air cholangiogram is not inferior to dye cholangiogram for malignant hilar biliary obstruction: a randomized study of efficacy and safety. *Indian J Gastroenterol*. 2014;33(6):537-542. doi:10.1007/S12664-014-0516-5
261. Cennamo V, Fuccio L, Zagari RM, et al. Can a wire-guided cannulation technique increase bile duct cannulation rate and prevent post-ERCP pancreatitis?: A meta-analysis of randomized controlled trials. *Am J Gastroenterol*. 2009;104(9):2343-2350. doi:10.1038/ajg.2009.269
262. Shao LM, Chen QY, Chen MY, Cai JT. Can wire-guided cannulation reduce the risk of post-endoscopic retrograde cholangiopancreatography pancreatitis? A meta-analysis of randomized controlled trials. *J Gastroenterol Hepatol*. 2009;24(11):1710-1715. doi:10.1111/J.1440-1746.2009.06010.X
263. Baron TH. Palliation of malignant obstructive jaundice. *Gastroenterol Clin North Am*. 2006;35(1):101-112. doi:10.1016/j.gtc.2006.01.001
264. Moole H, Jaeger A, Cashman M, et al. Are self-expandable metal stents superior to plastic stents in palliating malignant distal biliary strictures? A meta-analysis and systematic review. *Med J Armed Forces India*. 2017;73(1):42-48. doi:10.1016/j.mjafi.2016.08.014
265. Davids PH, Groen AK, Rauws EA, Tytgat GN, Huibregtse K. Randomised trial of self-expanding metal stents versus polyethylene stents for distal malignant biliary obstruction. *Lancet*. 1992;340(8834-8835):1488-1492. doi:10.1016/0140-6736(92)92752-2

266. Moss AC, Morris E, Mac Mathuna P. Palliative biliary stents for obstructing pancreatic carcinoma. *Cochrane Database Syst Rev*. 2006;1:CD004200. doi:10.1002/14651858.CD004200.pub2
267. Kaassis M, Boyer J, Dumas R, et al. Plastic or metal stents for malignant stricture of the common bile duct? Results of a randomized prospective study. *Gastrointest Endosc*. 2003;57(2):178-182. doi:10.1067/mge.2003.66
268. Artifon ELA, Sakai P, Ishioka S, et al. Endoscopic sphincterotomy before deployment of covered metal stent is associated with greater complication rate: a prospective randomized control trial. *J Clin Gastroenterol*. 2008;42(7):815-819. doi:10.1097/mcg.0b013e31803dcd8a
269. Banerjee N, Hilden K, Baron TH, Adler DG. Endoscopic biliary sphincterotomy is not required for transpapillary SEMS placement for biliary obstruction. *Dig Dis Sci*. 2011;56(2):591-595. doi:10.1007/S10620-010-1317-Z
270. ASGE Technology Committee; Kaul V, Adler DG, et al. Interventional EUS. *Gastrointest Endosc*. 2010;72(1):1-4. doi:10.1016/j.gie.2010.01.023
271. Inamdar S, Slattery E, Bhalla R, Sejpal DV, Trindade AJ. Comparison of adverse events for endoscopic vs percutaneous biliary drainage in the treatment of malignant biliary tract obstruction in an inpatient national cohort. *JAMA Oncol*. 2016;2(1):112-117. doi:10.1001/jamaoncol.2015.3670
272. Gao F, Bai Y, Ma SR, Liu F, Li ZS. Systematic review: photodynamic therapy for unresectable cholangiocarcinoma. *J Hepatobiliary Pancreat Sci*. 2010;17(2):125-131. doi:10.1007/S00534-009-0109-3
273. Kahaleh M, Mishra R, Shami VM, et al. Unresectable cholangiocarcinoma: comparison of survival in biliary stenting alone versus stenting with photodynamic therapy. *Clin Gastroenterol Hepatol*. 2008;6(3):290-297. doi:10.1016/j.cgh.2007.12.004
274. Wiedmann M, Berr F, Schiefke I, et al. Photodynamic therapy in patients with non-resectable hilar cholangiocarcinoma: 5-year follow-up of a prospective phase II study. *Gastrointest Endosc*. 2004;60(1):68-75. doi:10.1016/S0016-5107(04)01288-X
275. Dumoulin FL, Gerhardt T, Fuchs S, et al. Phase II study of photodynamic therapy and metal stent as palliative treatment for nonresectable hilar cholangiocarcinoma. *Gastrointest Endosc*. 2003;57(7):860-867. doi:10.1016/S0016-5107(03)70021-2
276. Ortner MEJ, Caca K, Berr F, et al. Successful photodynamic therapy for nonresectable cholangiocarcinoma: a randomized prospective study. *Gastroenterology*. 2003;125(5):1355-1363. doi:10.1016/j.gastro.2003.07.015
277. Lu Y, Liu L, Wu JC, Bie LK, Gong B. Efficacy and safety of photodynamic therapy for unresectable cholangiocarcinoma: a meta-analysis. *Clin Res Hepatol Gastroenterol*. 2015;39(6):718-724. doi:10.1016/j.clinre.2014.10.015
278. Witzigmann H, Berr F, Ringel U, et al. Surgical and palliative management and outcome in 184 patients with hilar cholangiocarcinoma: palliative photodynamic therapy plus stenting is comparable to R1/R2 resection. *Ann Surg*. 2006;244(2):230-239. doi:10.1097/01.sla.0000217639.10331.47
279. Wiedmann M, Caca K, Berr F, et al. Neoadjuvant photodynamic therapy as a new approach to treating hilar cholangiocarcinoma: a phase II pilot study. *Cancer*. 2003;97(11):2783-2790. doi:10.1002/cncr.11401
280. Wagner A, Wiedmann M, Tannapfel A, et al. Neoadjuvant downsizing of hilar cholangiocarcinoma with photodynamic therapy—long-term outcome of a phase II pilot study. *Int J Mol Sci*. 2015;16(11):26619-26628. doi:10.3390/ijms161125978
281. Aljiffry M, Walsh MJ, Molinari M. Advances in diagnosis, treatment and palliation of cholangiocarcinoma: 1990-2009. *World J Gastroenterol*. 2009;15(34):4240. doi:10.3748/wjg.15.4240
282. Iqbal S, Stevens PD. Cholangiopancreatoscopy for targeted biopsies of the bile and pancreatic ducts. *Gastrointest Endosc Clin N Am*. 2009;19(4):567-577. doi:10.1016/j.giec.2009.06.005
283. Awadallah NS, Chen YK, Piraka C, Antillon MR, Shah RJ. Is there a role for cholangioscopy in patients with primary sclerosing cholangitis? *Am J Gastroenterol*. 2006;101(2):284-291. doi:10.1111/J.1572-0241.2006.00383.X
284. Shah RJ, Langer DA, Antillon MR, Chen YK. Cholangioscopy and cholangioscopic forceps biopsy in patients with indeterminate pancreaticobiliary pathology. *Clin Gastroenterol Hepatol*. 2006;4(2):219-225. doi:10.1016/S1542-3565(05)00979-1
285. Piraka C, Shah RJ, Awadallah NS, Langer DA, Chen YK. Transpapillary cholangioscopy-directed lithotripsy in patients with difficult bile duct stones. *Clin Gastroenterol Hepatol*. 2007;5(11):1333-1338. doi:10.1016/j.cgh.2007.05.021
286. Ponchon T, Chavaillon A, Ayela P, Lambert R. Retrograde biliary ultrathin endoscopy enhances biopsy of stenoses and lithotripsy. *Gastrointest Endosc*. 1989;35(4):292-297. doi:10.1016/S0016-5107(89)72794-2
287. Seo DW, Lee SK, Yoo KS, et al. Cholangioscopic findings in bile duct tumors. *Gastrointest Endosc*. 2000;52(5):630-634. doi:10.1067/mge.2000.108667
288. Ross AS, Kozarek RA. Cholangioscopy: where are we now? *Curr Opin Gastroenterol*. 2009;25(3):245-251. doi:10.1097/MOG.0b013e328329236c
289. Chen YK, Pleskow DK. SpyGlass single-operator peroral cholangiopancreatoscopy system for the diagnosis and therapy of bile-duct disorders: a clinical feasibility study (with video). *Gastrointest Endosc*. 2007;65(6):832-841. doi:10.1016/j.gie.2007.01.025
290. Sethi A, Chen YK, Austin GL, et al. ERCP with cholangiopancreatoscopy may be associated with higher rates of complications than ERCP alone: a single-center experience. *Gastrointest Endosc*. 2011;73(2):251-256. doi:10.1016/j.gie.2010.08.058
291. Abu-Hamda EM, Baron TH. Endoscopic management of cholangiocarcinoma. *Semin Liver Dis*. 2004;24(2):165-175. doi:10.1055/S-2004-828893
292. Meara RS, Jhala D, Eloubeidi MA, et al. Endoscopic ultrasound-guided FNA biopsy of bile duct and gallbladder: analysis of 53 cases. *Cytopathology*. 2006;17(1):42-49. doi:10.1111/j.1365-2303.2006.00319.x
293. Rosch T, Hofrichter K, Frimberger E, et al. ERCP or EUS for tissue diagnosis of biliary strictures? A prospective comparative study. *Gastrointest Endosc*. 2004;60(3):390-396. doi:10.1016/S0016-5107(04)01732-8
294. Fritscher-Ravens A, Broering DC, Sriram PVJ, et al. EUS-guided fine-needle aspiration cytodiagnosis of hilar cholangiocarcinoma: a case series. *Gastrointest Endosc*. 2000;52(4):534-540. doi:10.1067/mge.2000.109589
295. Eloubeidi MA, Chen VK, Jhala NC, et al. Endoscopic ultrasound-guided fine needle aspiration biopsy of suspected cholangiocarcinoma. *Clin Gastroenterol Hepatol*. 2004;2(3):209-213. doi:10.1016/S1542-3565(04)00005-9
296. DeWitt J, Misra VL, LeBlanc JK, McHenry L, Sherman S. EUS-guided FNA of proximal biliary strictures after negative ERCP brush cytology results. *Gastrointest Endosc*. 2006;64(3):325-333. doi:10.1016/j.gie.2005.11.064
297. Gleeson FC, Rajan E, Levy MJ, et al. EUS-guided FNA of regional lymph nodes in patients with unresectable hilar cholangiocarcinoma. *Gastrointest Endosc*. 2008;67(3):438-443. doi:10.1016/j.gie.2007.07.018
298. Sai JK, Suyama M, Kubokawa Y, Watanabe S, Maehara T. Early detection of extrahepatic bile-duct carcinomas in the nonicteric stage by using MRCP followed by EUS. *Gastrointest Endosc*. 2009;70(1):29-36. doi:10.1016/j.gie.2008.10.036

299. Surveillance, Epidemiology, and End Results Program; National Cancer Institute. Cancer Stat Facts—Pancreatic Cancer. Accessed April 10, 2022. https://seer.cancer.gov/statfacts/html/pancreas.html
300. Khalaf N, El-Serag HB, Abrams HR, Thrift AP. Burden of pancreatic cancer: from epidemiology to practice. *Clin Gastroenterol Hepatol*. 2021;19(5):876-884. doi:10.1016/j.cgh.2020.02.054
301. Eloubeidi MA, Decker GA, Chandrasekhara V, et al. The role of endoscopy in the evaluation and management of patients with solid pancreatic neoplasia. *Gastrointest Endosc*. 2016;83(1):17-28. doi:10.1016/j.gie.2015.09.009
302. Mizrahi JD, Surana R, Valle JW, Shroff RT. Pancreatic cancer. *Lancet*. 2020;395(10242):2008-2020. doi:10.1016/S0140-6736(20)30974-0
303. American Cancer Society. Key Statistics for Pancreatic Cancer. Accessed April 10, 2022. https://www.cancer.org/cancer/pancreatic-cancer/about/key-statistics.html
304. Klein AP. Pancreatic cancer epidemiology: understanding the role of lifestyle and inherited risk factors. *Nat Rev Gastroenterol Hepatol*. 2021;18(7):493-502. doi:10.1038/s41575-021-00457-x
305. Shah I, Wadhwa V, Bilal M, et al. Prospective assessment for prediabetes and new-onset diabetes in high-risk individuals undergoing pancreatic cancer screening. *Gastroenterology*. 2021;161(5):1689-1691.e1. doi:10.1053/j.gastro.2021.06.055
306. Singhi AD, Koay EJ, Chari ST, Maitra A. Early detection of pancreatic cancer: opportunities and challenges. *Gastroenterology*. 2019;156(7):2024-2040. doi:10.1053/j.gastro.2019.01.259
307. Zerboni G, Signoretti M, Crippa S, Falconi M, Arcidiacono PG, Capurso G. Systematic review and meta-analysis: prevalence of incidentally detected pancreatic cystic lesions in asymptomatic individuals. *Pancreatology*. 2019;19(1):2-9. doi:10.1016/j.pan.2018.11.014
308. Aslanian HR, Lee JH, Canto MI. AGA clinical practice update on pancreas cancer screening in high-risk individuals: expert review. *Gastroenterology*. 2020;159(1):358-362. doi:10.1053/j.gastro.2020.03.088
309. Goggins M, Overbeek KA, Brand R, et al. Management of patients with increased risk for familial pancreatic cancer: updated recommendations from the International Cancer of the Pancreas Screening (CAPS) Consortium. *Gut*. 2020;69(1):7-17. doi:10.1136/gutjnl-2019-319352
310. DaVee T, Coronel E, Papafragkakis C, et al. Pancreatic cancer screening in high-risk individuals with germline genetic mutations. *Gastrointest Endosc*. 2018;87(6):1443-1450. doi:10.1016/j.gie.2017.12.019
311. Gonzalez A, Wadhwa V, Singh H, et al. Endoscopic ultrasound with combined fine needle aspiration plus biopsy improves diagnostic yield in solid pancreatic masses. *Scand J Gastroenterol*. 2022;57(5):610-617. doi:10.1080/00365521.2021.2024249
312. Andersen JR, Sorensen SM, Kruse A, Rokkjaer M, Matzen P. Randomised trial of endoscopic endoprosthesis versus operative bypass in malignant obstructive jaundice. *Gut*. 1989;30(8):1132-1135. doi:10.1136/gut.30.8.1132
313. Nakai Y, Isayama H, Wang HP, et al. International consensus statements for endoscopic management of distal biliary stricture. *J Gastroenterol Hepatol*. 2020;35(6):967-979. doi:10.1111/JGH.14955
314. Han SY, Kim SO, So H, Shin E, Kim DU, Park DH. EUS-guided biliary drainage versus ERCP for first-line palliation of malignant distal biliary obstruction: a systematic review and meta-analysis. *Sci Rep*. 2019;9(1):16551. doi:10.1038/s41598-019-52993-x
315. van Der Gaag NA, Rauws EAJ, van Eijck CHJ, et al. Preoperative biliary drainage for cancer of the head of the pancreas. *N Engl J Med*. 2010;362(2):129-137. doi:10.1056/nejmoa0903230
316. Palta M, Godfrey D, Goodman KA, et al. Radiation therapy for pancreatic cancer: executive summary of an ASTRO clinical practice guideline. *Pract Radiat Oncol*. 2019;9(5):322-332. doi:10.1016/j.prro.2019.06.016
317. Coronel E, Singh BS, Cazacu IM, et al. EUS-guided placement of fiducial markers for the treatment of pancreatic cancer. *VideoGIE*. 2019;4(9):403-406. doi:10.1016/j.vgie.2019.05.007
318. Coronel E, Cazacu IM, Sakuraba A, et al. EUS-guided fiducial placement for GI malignancies: a systematic review and meta-analysis. *Gastrointest Endosc*. 2019;89(4):659-670.e18. doi:10.1016/j.gie.2018.10.047
319. Micames C, Jowell PS, White R, et al. Lower frequency of peritoneal carcinomatosis in patients with pancreatic cancer diagnosed by EUS-guided FNA vs. percutaneous FNA. *Gastrointest Endosc*. 2003;58(5):690-695. doi:10.1016/S0016-5107(03)02009-1
320. Koulouris AI, Banim P, Hart AR. Pain in patients with pancreatic cancer: prevalence, mechanisms, management and future developments. *Dig Dis Sci*. 2017;62(4):861-870. doi:10.1007/S10620-017-4488-z
321. Koulouris AI, Alexandre L, Hart AR, Clark A. Endoscopic ultrasound-guided celiac plexus neurolysis (EUS-CPN) technique and analgesic efficacy in patients with pancreatic cancer: a systematic review and meta-analysis. *Pancreatology*. 2021;21(2):434-442. doi:10.1016/j.pan.2020.12.016
322. Cazacu IM, Singh BS, Saftoiu A, Bhutani MS. Endoscopic ultrasound-guided treatment of pancreatic cancer. *Curr Gastroenterol Rep*. 2020;22(6):27. doi:10.1007/S11894-020-00767-1
323. Thosani N, Sharma NR, Raijman I, et al. 483 Safety and efficacy of endoscopic ultrasound guided radiofrequency ablation (EUS-RFA) in the treatment of pancreatic lesions: a multi-center experience [abstract]. *Gastrointest Endosc*. 2018;87(6 suppl):AB84. doi:10.1016/j.gie.2018.04.092
324. Song TJ, Seo DW, Lakhtakia S, et al. Initial experience of EUS-guided radiofrequency ablation of unresectable pancreatic cancer. *Gastrointest Endosc*. 2016;83(2):440-443. doi:10.1016/j.gie.2015.08.048
325. Carrafiello G, Lagana D, Recaldini C, et al. Radiofrequency ablation of a pancreatic metastasis from renal cell carcinoma: case report. *Surg Laparosc Endosc Percutan Tech*. 2008;18(1):64-66. doi:10.1097/SLE.0b013e3181592a13
326. Elias D, Baton O, Sideris L, Lasser P, Pocard M. Necrotizing pancreatitis after radiofrequency destruction of pancreatic tumours. *Eur J Surg Oncol*. 2004;30(1):85-87. doi:10.1016/j.ejso.2003.10.013
327. Pandya G, Shelat VG. Radiofrequency ablation of pancreatic ductal adenocarcinoma: the past, the present and the future. *World J Gastrointest Oncol*. 2015;7(2):6-11. doi:10.4251/wjgo/v7.i2.6
328. Oh D, Ko SW, Seo DW, et al. Endoscopic ultrasound-guided radiofrequency ablation of pancreatic microcystic serous cystic neoplasms: a retrospective study. *Endoscopy*. 2021;53(7):739-743. doi:10.1055/A-1250-7786
329. Barthet M, Giovannini M, Lesavre N, et al. Endoscopic ultrasound-guided radiofrequency ablation for pancreatic neuroendocrine tumors and pancreatic cystic neoplasms: a prospective multicenter study. *Endoscopy*. 2019;51(9):836-842. doi:10.1055/A-0824-7067
330. Scopelliti F, Pea A, Conigliaro R, et al. Technique, safety, and feasibility of EUS-guided radiofrequency ablation in unresectable pancreatic cancer. *Surg Endosc*. 2018;32(9):4022-4028. doi:10.1007/S00464-018-6217-X
331. Francesco S, Gastroenterology C, Crino SF, et al. EUS-guided radiofrequency ablation (EUS-RFA) of solid pancreatic neoplasm using an 18-gauge needle electrode: feasibility, safety, and technical success. *J Gastrointest Liver Dis*. 2018;27(1):67-72. doi:10.15403/jgld.2014.1121.271.eus
332. Song TJ, Seo DW, Lakhtakia S, et al. Initial experience of EUS-guided radiofrequency ablation of unresectable pancreatic cancer. *Gastrointest Endosc*. 2016;83(2):440-443. doi:10.1016/j.gie.2015.08.048

333. Lakhtakia S, Ramchandani M, Gupta R, Venugopal S, Galasso D, Reddy N. Mo1494 EUS-guided radiofrequency ablation (EUS-RFA) using a novel internally cooled needle electrode for pancreatic insulinoma: a case series in humans [abstract]. *Gastrointest Endosc*. 2015;81(5 suppl):AB440. doi:10.1016/j.gie.2015.03.824
334. Wang D, Jin Z, Lei W, Leung J, Endoscopy ZLG. Mo1524 Endoscopic ultrasound guided radiofrequency ablation for the treatment of advanced pancreatic carcinoma. *Gastrointest Endosc*. 2013;77(5 suppl):AB414. doi:10.1016/j.gie.2013.03.272
335. Pai M, Senturk H, Lakhtakia S, et al. 351 Endoscopic ultrasound guided radiofrequency ablation (EUS-RFA) for cystic neoplasms and neuroendocrine tumors of the pancreas. *Gastrointest Endosc*. 2013;77(5 suppl):AB143-AB144. doi:10.1016/j.gie.2013.04.058
336. Paiella S, Salvia R, Ramera M, et al. Local ablative strategies for ductal pancreatic cancer (radiofrequency ablation, irreversible electroporation): a review. *Gastroenterol Res Pract*. 2016;2016:4508376. doi:10.1155/2016/4508376
337. Chu KF, Dupuy DE. Thermal ablation of tumours: biological mechanisms and advances in therapy. *Nat Rev Cancer*. 2014;14:199-208. doi:10.1038/nrc3672
338. Yousaf MN, Ehsan H, Muneeb A, et al. Role of radiofrequency ablation in the management of unresectable pancreatic cancer. *Front Med (Lausanne)*. 2021;7:624997. doi:10.3389/fmed.2020.624997/BIBTEX
339. Girelli R, Frigerio I, Giardino A, et al. Results of 100 pancreatic radiofrequency ablations in the context of a multimodal strategy for stage III ductal adenocarcinoma. *Langenbecks Arch Surg*. 2013;398(1):63-69. doi:10.1007/S00423-012-1011-Z
340. Spiliotis JD, Datsis AC, Michalopoulos NV, et al. Radiofrequency ablation combined with palliative surgery may prolong survival of patients with advanced cancer of the pancreas. *Langenbecks Arch Surg*. 2007;392(1):55-60. doi:10.1007/S00423-006-0098-5
341. Cantore M, Girelli R, Mambrini A, et al. Combined modality treatment for patients with locally advanced pancreatic adenocarcinoma. *Br J Surg*. 2012;99(8):1083-1088. doi:10.1002/BJS.8789
342. Thosani N, Cen P, Rowe J, et al. Long-term outcomes of endoscopic ultrasound-guided radiofrequency ablation (EUS-RFA) for advanced pancreatic and periampullary adenocarcinoma. *medRxiv*. Published online December 14, 2021. doi:10.1101/2021.12.11.21267660
343. Zhang L, Tan S, Huang S, et al. The safety and efficacy of endoscopic ultrasound-guided ablation therapy for solid pancreatic tumors: a systematic review. *Scand J Gastroenterol*. 2020;55(9):1121-1131. doi:10.1080/00365521.2020.1797870
344. Date RS. Current status of local ablative techniques in the treatment of pancreatic cancer. *Pancreas*. 2006;33(2):198-199. doi:10.1097/01.mpa.0000229006.39667.ea
345. Giardino A, Girelli R, Frigerio I, et al. Triple approach strategy for patients with locally advanced pancreatic carcinoma. *HPB*. 2013;15(8):623-627. doi:10.1111/hpb.12027
346. Girelli R, Frigerio I, Salvia R, Barbi E, Tinazzi Martini P, Bassi C. Feasibility and safety of radiofrequency ablation for locally advanced pancreatic cancer. *Br J Surg*. 2010;97(2):220-225. doi:10.1002/bjs.6800
347. Lee JH, Kedia P, Stavropoulos SN, Carr-Locke D. AGA clinical practice update on endoscopic management of perforations in gastrointestinal tract: expert review. *Clin Gastroenterol Hepatol*. 2021;19(11):2252-2261.e2. doi:10.1016/j.cgh.2021.06.045
348. Rombouts SJE, Vogel JA, van Santvoort HC, et al. Systematic review of innovative ablative therapies for the treatment of locally advanced pancreatic cancer. *Br J Surg*. 2015;102(3):182-193. doi:10.1002/bjs.9716
349. Fegrachi S, Molenaar IQ, Klaessens JH, et al. Radiofrequency ablation of the pancreas with and without intraluminal duodenal cooling in a porcine model. *J Surg Res*. 2013;184(2):867-872. doi:10.1016/j.jss.2013.04.068
350. The University of Texas Health Science Center. Endoscopic Ultrasound PANcreatic CAncer RaDIofrequeNcy AbLation (PANCARDINAL-1). ClinicalTrials.gov identifier NCT04990609. Accessed April 10, 2022. https://clinicaltrials.gov/ct2/show/NCT04990609
351. Surveillance, Epidemiology, and End Results Program; National Cancer Institute. Cancer Stat Facts: Small Intestine Cancer. Accessed April 9, 2022. https://seer.cancer.gov/statfacts/html/smint.html
352. Chung CS, Tai CM, Huang TY, et al. Small bowel tumors: a Digestive Endoscopy Society of Taiwan (DEST) multicenter enteroscopy-based epidemiologic study. *J Formos Med Assoc*. 2018;117(8):705-710. doi:10.1016/j.jfma.2017.09.003
353. Bilimoria KY, Bentrem DJ, Wayne JD, Ko CY, Bennett CL, Talamonti MS. Small bowel cancer in the United States: changes in epidemiology, treatment, and survival over the last 20 years. *Ann Surg*. 2009;249(1):63-71. doi:10.1097/SLA.0b013e31818e4641
354. McLaughlin PD, Maher MM. Primary malignant diseases of the small intestine. *AJR Am J Roentgenol*. 2013;201(1):W9-W14. doi:10.2214/ajr.12.8492
355. Khan K, Peckitt C, Sclafani F, et al. Prognostic factors and treatment outcomes in patients with small bowel adenocarcinoma (SBA): the Royal Marsden Hospital (RMH) experience. *BMC Cancer*. 2015;15:15. doi:10.1186/s12885-015-1014-6
356. Haselkorn T, Whittemore AS, Lilienfeld DE. Incidence of small bowel cancer in the United States and worldwide: geographic, temporal, and racial differences. *Cancer Causes Control*. 2005;16(7):781-787. doi:10.1007/S10552-005-3635-6
357. Weiss NS, Yang CP. Incidence of histologic types of cancer of the small intestine. *J Natl Cancer Inst*. 1987;78(4):653-656. doi:10.1093/jnci/78.4.653
358. Neugut AI, Jacobson JS, Suh S, Mukherjee R, Arber N. The epidemiology of cancer of the small bowel. *Cancer Epidemiol Biomarkers Prev*. 1998;7(3):243-251.
359. Raghav K, Overman MJ. Small bowel adenocarcinomas—existing evidence and evolving paradigms. *Nat Rev Clin Oncol*. 2013;10(9):534-544. doi:10.1038/nrclinonc.2013.132
360. Wheeler JMD, Warren BF, Mortensen NJMC, et al. An insight into the genetic pathway of adenocarcinoma of the small intestine. *Gut*. 2002;50(2):218-223. doi:10.1136/gut.50.2.218
361. Aparicio T, Svrcek M, Henriques J, et al. Panel gene profiling of small bowel adenocarcinoma: results from the NADEGE prospective cohort. *Int J Cancer*. 2021;148(7):1731-1742. doi:10.1002/ijc.33392
362. American Cancer Society. Risk Factors for Small Intestine Cancer (Adenocarcinoma). Accessed April 9, 2022. https://www.cancer.org/cancer/small-intestine-cancer/causes-risks-prevention/risk-factors.html
363. Wu AH, Yu MC, Mack TM. Smoking, alcohol use, dietary factors and risk of small intestinal adenocarcinoma. *J Cancer*. 1997;70(5):512-517. doi:10.1002/(sici)1097-0215(19970304)70:5<512::aid-ijc4>3.0.co;2-0
364. Yamada A, Komaki Y, Komaki F, Micic D, Zullow S, Sakuraba A. Risk of gastrointestinal cancers in patients with cystic fibrosis: a systematic review and meta-analysis. *Lancet Oncol*. 2018;19(6):758-767. doi:10.1016/S1470-2045(18)30188-8
365. Solem CA, Harmsen WS, Zinsmeister AR, Loftus EV Jr. Small intestinal adenocarcinoma in Crohn's disease: a case-control study. *Inflamm Bowel Dis*. 2004;10(1):32-35. doi:10.1097/00054725-200401000-00005
366. Canavan C, Abrams KR, Mayberry JF. Meta-analysis: mortality in Crohn's disease. *Aliment Pharmacol Ther*. 2007;25(8):861-870. doi:10.1111/J.1365-2036.2007.03276.X
367. Howdle PD, Jalal PK, Holmes GKT, Houlston RS. Primary small-bowel malignancy in the UK and its association with coeliac disease. *QJM*. 2003;96(5):345-353. doi:10.1093/qjmed/hcg058
368. Green PH, Jabri B. Celiac disease and other precursors to small-bowel malignancy. *Hematol Clin*. 2003;17(2):611-624. doi:10.1016/S0889-8588(03)00008-X
369. Jess T, Winther KV, Munkholm P, Langholz E, Binder V. Intestinal and extra-intestinal cancer in Crohn's disease: follow-up of a

population-based cohort in Copenhagen County, Denmark. *Aliment Pharmacol Ther*. 2004;19(3):287-293. doi:10.1111/J.1365-2036.2004.01858.X

370. Naef M, Buhlmann M, Baer HU. Small bowel tumors: diagnosis, therapy and prognostic factors. *Langenbecks Arch Surg*. 1999;384(2):176-180. doi:10.1007/s004230050188
371. Maglinte DD, O'Connor K, Bessette J, Chernish SM, Kelvin FM. The role of the physician in the late diagnosis of primary malignant tumors of the small intestine. *Am J Gastroenterol*. 1991;86(3):304-308.
372. Lewis BS, Eisen GM, Friedman S. A pooled analysis to evaluate results of capsule endoscopy trials. *Endoscopy*. 2005;37(10):960-965. doi:10.1055/S-2005-870353
373. Pennazio M, Spada C, Eliakim R, et al. Small-bowel capsule endoscopy and device-assisted enteroscopy for diagnosis and treatment of small-bowel disorders: European Society of Gastrointestinal Endoscopy (ESGE) clinical guideline. *Endoscopy*. 2015;47(4):352-376. doi:10.1055/S-0034-1391855
374. Appleyard M, Glukhovsky A, Swain P. Wireless-capsule diagnostic endoscopy for recurrent small-bowel bleeding. *N Engl J Med*. 2009;344(3):232-233. doi:10.1056/nejm200101183440316
375. Hakim FA, Alexander JA, Huprich JE, Grover M, Enders FT. CT-enterography may identify small bowel tumors not detected by capsule endoscopy: eight years' experience at Mayo Clinic Rochester. *Dig Dis Sci*. 2011;56(10):2914-2919. doi:10.1007/S10620-011-1773-0
376. Matsumoto T, Moriyama T, Esaki M, Nakamura S, Iida M. Performance of antegrade double-balloon enteroscopy: comparison with push enteroscopy. *Gastrointest Endosc*. 2005;62(3):392-398. doi:10.1016/j.gie.2005.04.052
377. May A, Nachbar L, Schneider M, Ell C. Prospective comparison of push enteroscopy and push-and-pull enteroscopy in patients with suspected small-bowel bleeding. *Am J Gastroenterol*. 2006;101(9):2016-2024. doi:10.1111/J.1572-0241.2006.00745.X
378. Lenz P, Domagk D. Double- vs. single-balloon vs. spiral enteroscopy. *Best Pract Res Clin Gastroenterol*. 2012;26(3):303-313. doi:10.1016/j.bpg.2012.01.021
379. Lee JH, Kedia P, Stavropoulos SN, Carr-Locke D. AGA clinical practice update on endoscopic management of perforations in gastrointestinal tract: expert review. *Clin Gastroenterol Hepatol*. 2021;19(11):2252-2261.e2. doi:10.1016/j.cgh.2021.06.045
380. Navaneethan U, Hasan MK, Lourdusamy V, Zhu X, Hawes RH, Varadarajulu S. Efficacy and safety of endoscopic mucosal resection of non-ampullary duodenal polyps: a systematic review. *Endosc Int Open*. 2016;4(6):E699-E708. doi:10.1055/S-0042-107069
381. Jamil LH, Kashani A, Peter N, Lo SK. Safety and efficacy of cap-assisted EMR for sporadic nonampullary duodenal adenomas. *Gastrointest Endosc*. 2017;86(4):666-672. doi:10.1016/j.gie.2017.02.023
382. Bartel MJ, Puri R, Brahmbhatt B, et al. Endoscopic and surgical management of nonampullary duodenal neoplasms. *Surg Endosc*. 2018;32(6):2859-2869. doi:10.1007/S00464-017-5994-Y
383. Lee JH, Yu AC, Ali FS, et al. The conundrum in endoscopic management of duodenal polyps: a tertiary cancer center experience. *Expert Rev Gasteroenterol Hepatol*. 2022;16(6):569-576. doi:10.1080/17474124.2022.2088508

How to cite this article: Wadhwa V, Patel N, Grover D, Ali FS, Thosani N. Interventional gastroenterology in oncology. *CA Cancer J Clin*. 2022;1-34. doi:10.3322/caac.21766